

PROCEEDINGS
OF THE
CALIFORNIA ACADEMY OF SCIENCES
FOURTH SERIES



Vol. XXXIX, No. 20, pp. 411-500; 72 figs.

December 19, 1973

MUSCULAR ANATOMY OF THE FORE-
LIMB OF THE SEA OTTER
(*ENHYDRA LUTRIS*)

By

L. D. Howard

Hopkins Marine Station of Stanford University, Pacific Grove, California 93950

INTRODUCTION

The present study was undertaken to make available for future reference the detailed muscular anatomy of the forelimb of this remarkable marine mammal, *Enhydra lutris*.

The sea otter has a limited southern range of approximately 140 miles along the coast of California from the Monterey Peninsula on the north to Morro Bay on the south. It is estimated by aerial and shoreline survey, that 1,000 individuals make up the population in this area.

The sea otter rarely comes on shore in this area, preferring the sanctuary of the abundant kelp beds for its home. Food preference is exclusively the many invertebrates found in this area, such as the various kinds of crabs, shellfish, and sea urchins. Since this food is mainly on the ocean floor, the animals dive to obtain it but return to the surface to consume it while floating on their backs using the chest as a dinner table. Divers, observing otters gathering their food, note that it is carried either in a bimanual manner or under one arm in the axillary area where a fold of skin assists in securing the object.

On occasions, an animal will bring up a rock and, placing it on its abdomen, use it as an anvil against which it can break shellfish. In so doing the animal holds the food between its forepaws and rapidly strikes it against the rock. In view of this habit, the otter has been classified as a tool user.

We are concerned, therefore, with the work this animal has to do with the

forelimbs in an aquatic environment, and the structural anatomy he has with which to accomplish these tasks.

Over the past several years, the author has observed these animals in their natural habitat, noting the high degree of specialized use of the forelimbs in eating, grooming, and caring for the young. Based on these observations it would appear that the 'hand' of this animal should be extremely dextrous, yet when observed at close range, the anatomical characteristics show marked resemblance to the forepaw of mammals which use the forelimb mainly for land propulsion.

Many references in the literature describe how the otter uses its forelimbs. It seemed of interest, therefore, to study the 'hand' in some detail from an anatomical standpoint. To do so necessitated the study of the entire forelimb since the hand, to be effective, must be positioned by the forelimb and positional stability maintained when the hand itself is in use.

The material for this study consisted of one fresh specimen on which the range of motion measurements were made, and one preserved specimen used for recording the detail of the muscular anatomy. The method used for this latter study was to make a series of anatomical dissections, photograph each, and then from the projected slides make accurate line drawings. In this way, the relative size and relationship of each muscle could be portrayed.

The forelimb muscles can be grouped in various ways: by their innervation, by their action (such as extensors and flexors), by their origin (pre- and post-axial), or by where they make their attachments. Examples of the last would be muscles connecting the trunk to the limb, muscles connecting the scapula to the humerus, etc.

In this treatise a fixed method of presentation is not used, but rather the muscles are described as they are encountered in a dissection going from the proximal to the distal areas. Each muscle is numbered and retains this number wherever it appears. A gross description of each muscle is given with its origin and insertion and a notation as to its action or actions if the muscle were to be activated as a single unit. This situation, of course, never happens in the living specimen, as each voluntary motion of any part of the limb is a complicated interplay between the many muscles, some relaxing, some serving to stabilize the joints, and some serving as prime movers for any given motion.

For further clarification, plates of the forearm skeleton have been added and the areas of origin and insertion of muscles designated.

OBSERVATIONS OF JOINT MOBILITY

In a fresh specimen, by means of passive motions, some idea of the range of motion of the forelimb could be observed and for some joints the range of motion could be actually recorded.

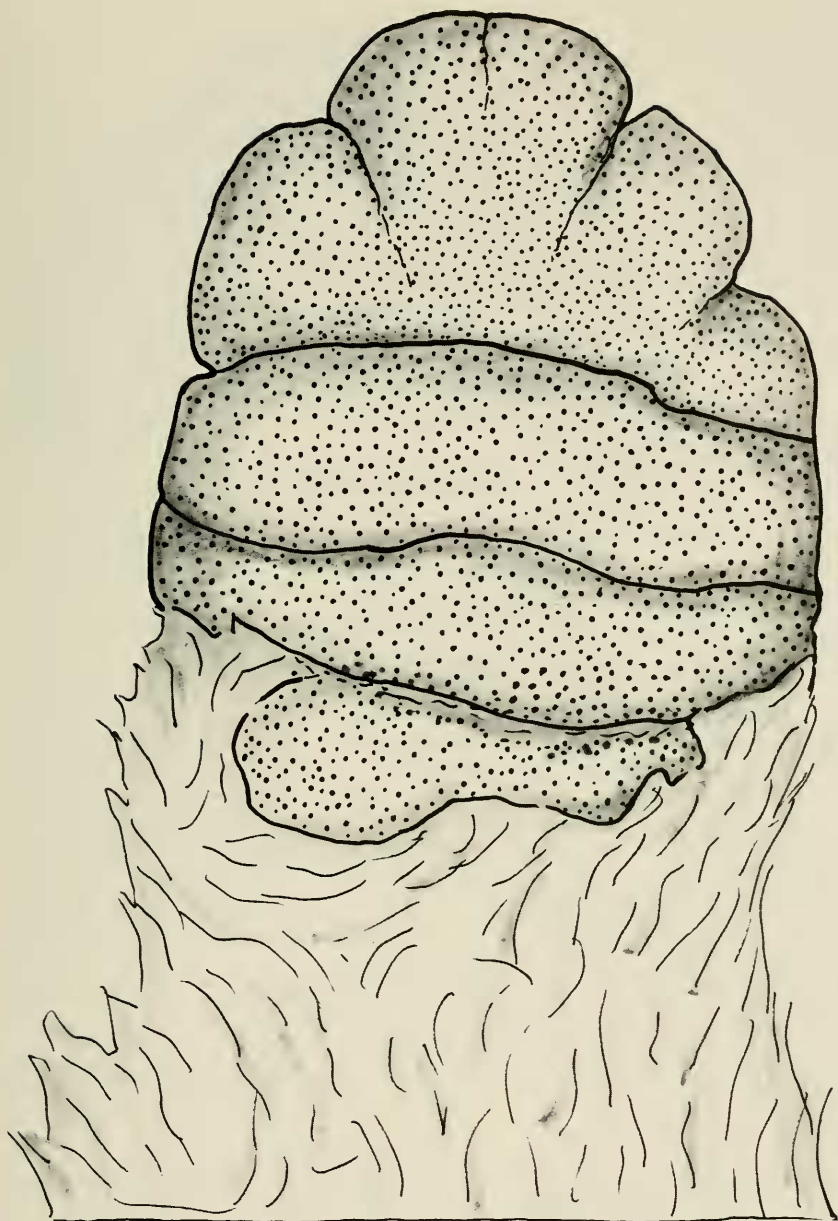


FIGURE 1. An anterior or palmar view of the forefoot to show the disposition of the palmar pads. The major crease lines are transverse and quite deep. Distally, shallow incomplete crease lines suggest interdigitation, but such is not the case to any practical degree. The pads appear to bulge slightly and are turgid, and the covering skin is thick with a pebbly roughness.

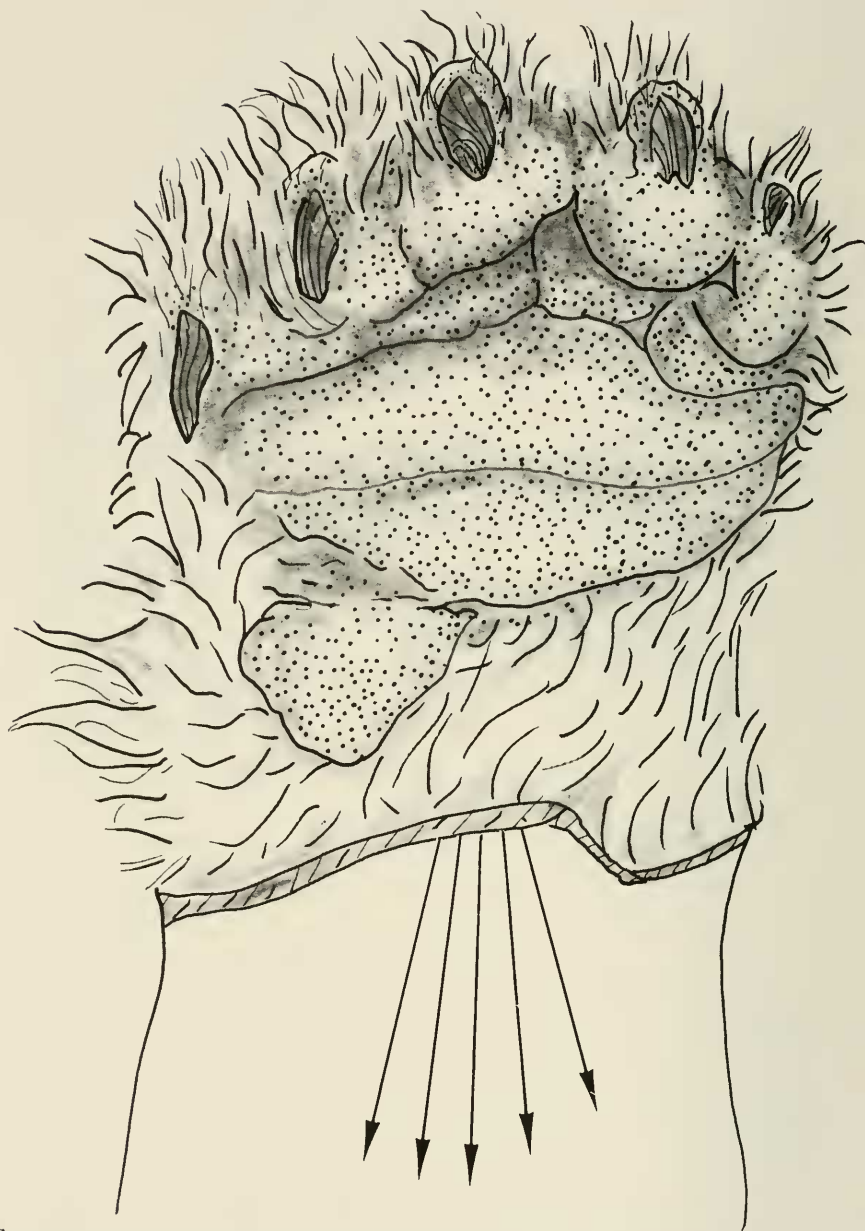


FIGURE 2. Anterior or palmar view of the forefoot while all long digital flexors are being pulled strongly in the forearm. Although there is cupping of the palm, the pad so fills the palm that there is little space in which to retain objects. Note that the claws now appear, as all interphalangeal and metacarpal phalangeal joints come into maximum flexion.

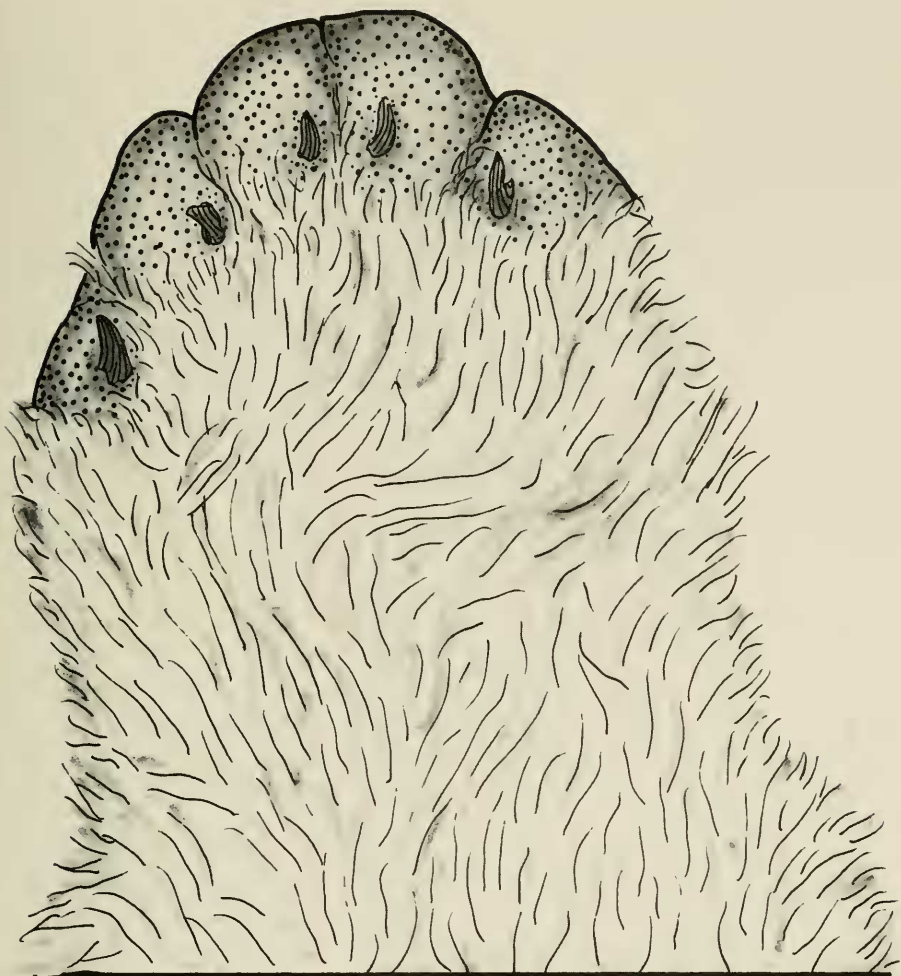


FIGURE 3. In this posterior or dorsal view of the forefoot the hair has been trimmed away to show the position of the claws which, in the unflexed hand, are visible only in this view. Since the claws are closely associated with, and move only with, the terminal phalanx, their position indicates a marked degree of hyperextension of the terminal digital joints.

As there is no clavicle in this animal, the pectoral girdle, which consists of the scapula only, is extremely mobile on the chest wall, being limited only by the muscles attaching the girdle to the trunk. Thus, in a transverse plane, the pectoral girdle could be moved to near the midline dorsally and ventrally, and in the longitudinal plane an equal, if not slightly greater, range of motion was present. A good range of motion in the shoulder joint was also present but tech-

nically it was not possible to get accurate measurements in degrees of abduction, adduction, flexion, extension, and rotation.

For the elbow, extension was to an angle of 145° and flexion to an angle of 40° .

For the forearm, pronation was to 30° beyond the midposition and supination to 45° beyond the midposition.

The wrist is very mobile. Palmar flexion of the wrist was to an angle of 82° beyond the straight line of the forearm, and dorsiflexion to an angle of 40° . Good lateral motion of the wrist was also present, radioflexion being to an angle of 30° and ulnaflexion to an angle of 50° .

For digits 2, 3, 4, and 5, the average range of motion of the individual joints as measured from the line of the metacarpal was as follows:

| | Extension | Flexion |
|--------------------------------|---------------|--------------|
| Metacarpal phalangeal joint | 80° | 45° |
| Proximal interphalangeal joint | 52° | 45° |
| Distal interphalangeal joint | 170° | 20° |
| For digit 1: | | |
| Metacarpal phalangeal joint | 80° | 65° |
| Interphalangeal joint | 170° | 50° |

From the above, it is to be noted that the digital joints have a greater range of extension than of flexion, which, in itself, would indicate the sacrificing of a gripping mechanism in favor of ambulatory functions.

This situation was even more evident when traction was made on the digital extensors and the flexor tendons in the forearm.

The digits of the 'hand' are not individualized, being held closely together by webbing and the first digit, or thumb, is in the same plane as the other digits. Without an established thumb web the first digit is unopposable and lateral motions of the other digits are of insignificant amount because of the webbing. In fact, a better term than "webbing" would be total syndactylism.

An effort was made to see if objects could be held in the hand by a grasp mechanism. When the long flexors were pulled upon strongly in the forearm an ordinary pencil, for example, could not be grasped firmly in the hand. Larger objects could be held but rather precariously in the absence of an opposable thumb. Part of the problem, as far as gripping objects is concerned, appears to be due to the large pads on the palmar surface which, on grasp, appear to fill the palm. When the digits were flexed to their limits, the terminal digital pads failed to touch the palmar pad by about 12 mm. However, there is sufficient flexion of the digits to allow the claws to be used against the flat opposing surface. Since palmar flexion of the wrist is extremely good, large objects of 8 or more cm. in diameter could be held between the hand and distal forearm.

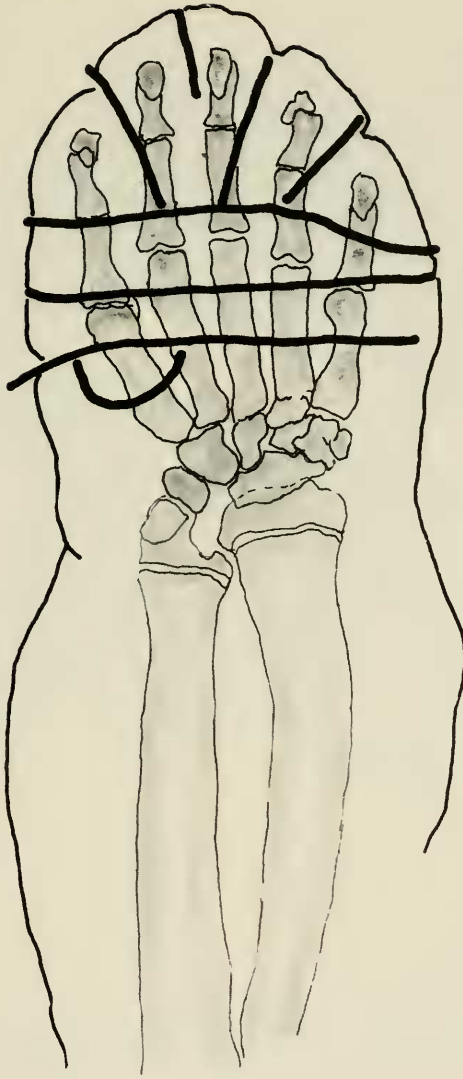


FIGURE 4. This figure is a direct line copy of an x-ray of the hand and wrist after soft iron wires were placed in the creases of the palmar pad. This was done to show the relationship of these crease lines to the underlying joints. The pad itself lies distal to the most proximal wire (heavy line). From this it is to be noted that the volar pad covers only the distal one-half of the metacarpals plus the phalanges. The main transverse creases are at metacarpal phalangeal joint level. Therefore when walking on this pad the otter does not walk on the flat of the hand as it appears, but rather on the metatarsal heads and the phalanges. This is readily understandable in view of the limited dorsiflexion of the wrist and the great degree of hyperextension of the metacarpal phalangeal joints.

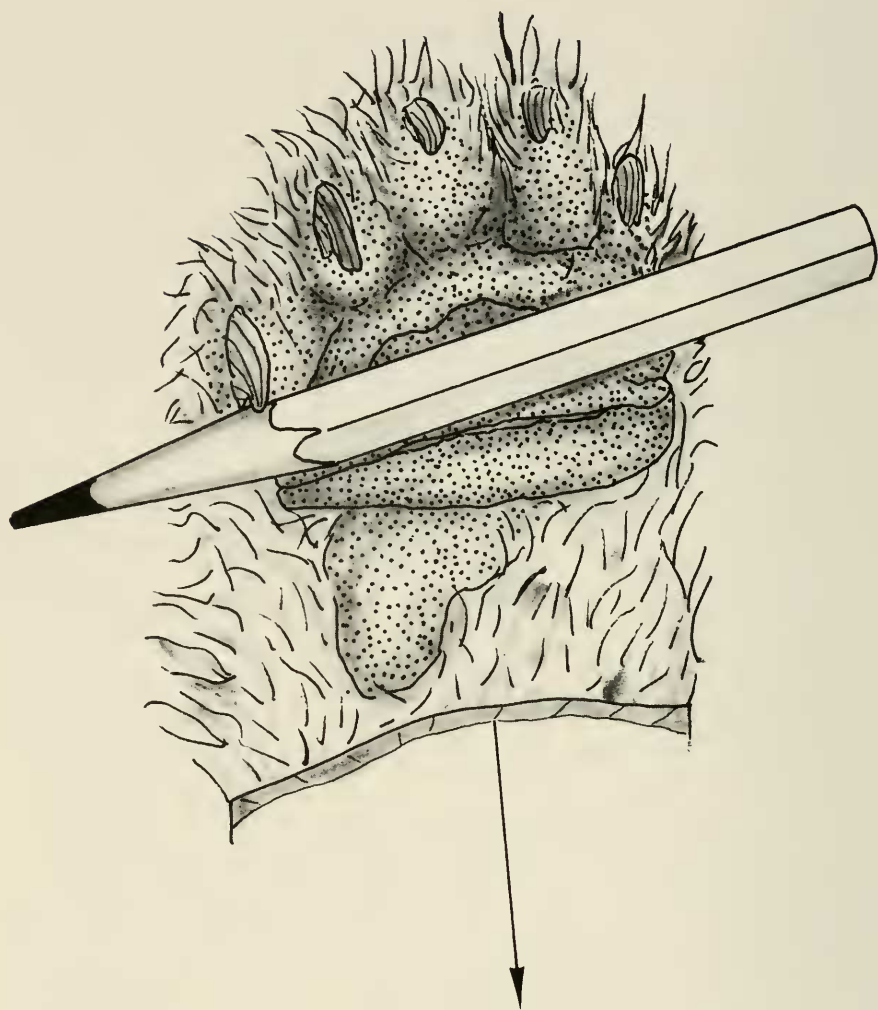


FIGURE 5. The grasp mechanism of the individual hand is markedly limited as shown in this figure. The long flexor tendons of the digits were pulled upon forcibly in an effort to demonstrate grasp of a pencil. This precarious grasp depended upon sufficient flexion of the finger joints to allow the claw of the fifth digit to become effective. Without a good claw (and the claws are frequently worn down to mere nubbins) it is doubtful that either of the objects shown in figures 5 and 6 could be held in the one hand. See also figure 6.

On the few occasions that the animal was observed on land, the forelimb functioned admirably for terrestrial progression. Underwater observers report that the forelimbs are not used for swimming, but are active in food gathering.

In light of these observations it is understandable why the animal performs

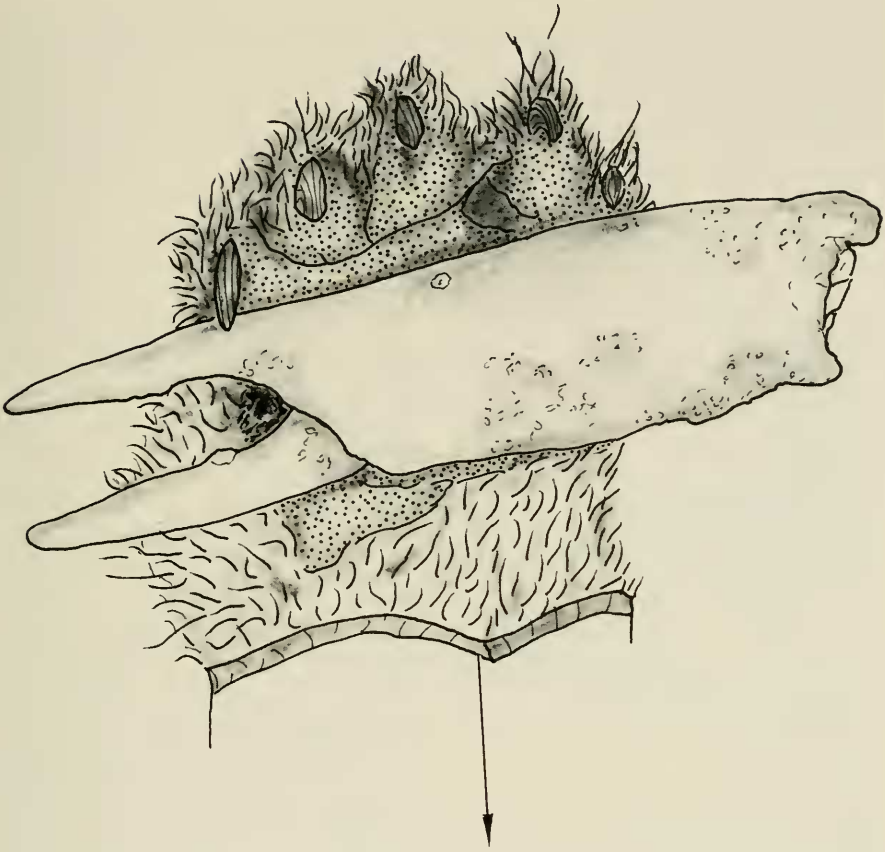


FIGURE 6. In this figure, a medium-sized crab leg has been substituted for the pencil of figure 5.

most of the forelimb functions in a bimanual manner. Anatomically, the hand is small, the digits are not individualized, and grasp function is poor. Therefore, to obtain the observed dexterity the forelimbs must be used together. One hand opposing the other provides what we would interpret as a 'thumb service.'

One is reminded of a bilateral human amputee who has lost both hands at wrist level, and in the absence of a prosthesis everything that can be done is done by opposing the two forearm stumps.

Thus it is interesting to speculate whether or not an otter could survive if one hand was lost. The probability seems good that he could, using the forearm stump against the opposite hand. However, to lose one extremity at elbow level would probably prove disastrous.

The anatomical study which follows was made on sea otter #222 (State of

California Fish and Game). The otter was an adult male with an overall body length (tip of nose to tip of tail) of 125 cm. The length of the upper arm was approximately 14 cm. and the lower arm was of equal length. The length of the forefoot (hand) was 7 cm. and the width was 5 cm. It must be kept in mind that only a single specimen was used and therefore variations and anomalies which are bound to occur between individual specimens are not recorded.

MUSCLES OF THE FORELIMB OF THE SEA OTTER

ALPHABETICAL LISTING OF MUSCLES

| Muscle | No. | Muscle | No. |
|--|-----|-----------------------------------|-----|
| Abductor digiti quinti | 49 | Flexor digitorum sublimis ulnaris | 48 |
| Abductor digiti secundi | 57 | Flexor pollicis brevis | 55 |
| Abductor pollicis brevis | 54 | Infraspinatus | 24 |
| Abductor pollicis longus | 38 | Interossei | 59 |
| Acromiodeltoideus | 17 | Latissimus dorsi | 15 |
| Acromiotrapezius | 2 | Levator anguli scapulae | 11 |
| Adductor digiti quinti | 52 | Lumbricali | 53 |
| Adductor digiti secundi | 57 | Omotracheon | 6 |
| Adductor pollicis | 56 | Opponens digiti quinti | 50 |
| Anconeus externus | 23 | Palmaris longus | 40 |
| Biceps brachii | 28 | Pectoantebrachialis | 12 |
| Brachialis | 29 | Pectoralis major | 13 |
| Brachioradialis | 30 | Pectoralis minor | 14 |
| Clavobrachialis | 5 | Pronator quadratus | 46 |
| Clavotrapezius | 3 | Pronator teres | 44 |
| Cleidomastoideus | 4 | Rhomboideus capitis | 8 |
| Dorsoepitrochlearis | 19 | Rhomboideus major | 7 |
| Extensor carpi radialis brevis | 32 | Rhomboideus profundus | 9 |
| Extensor carpi radialis longus | 31 | Serratus magnus | 10 |
| Extensor carpi ulnaris | 35 | Spinodeltoideus | 18 |
| Extensor digitorum communis | 33 | Spinotrapezius | 1 |
| Extensor digitorum lateralis | 34 | Subscapularis | 27 |
| Extensor pollicis et indicis longus | 36 | Supinator | 37 |
| Flexor carpi radialis | 43 | Supraspinatus | 26 |
| Flexor carpi ulnaris | 39 | Teres major | 16 |
| Flexor digitorum profundus, central head | 45 | Teres minor | 25 |
| Flexor digitorum profundus, humeral head | 42 | Triceps brachii caput lateralis | 21 |
| Flexor digitorum profundus, ulna head | 41 | Triceps brachii caput longus | 20 |
| Flexor digiti quinti brevis | 51 | Triceps brachii caput medialis | 22 |
| Flexor digitorum sublimis radialis | 47 | | |

DESCRIPTIONS OF MUSCLES

1. Spinotrapezius.

This muscle is the most posterior of the three muscles which make up the trapezius muscle complex. The spinotrapezius, with the acromiotrapezius and

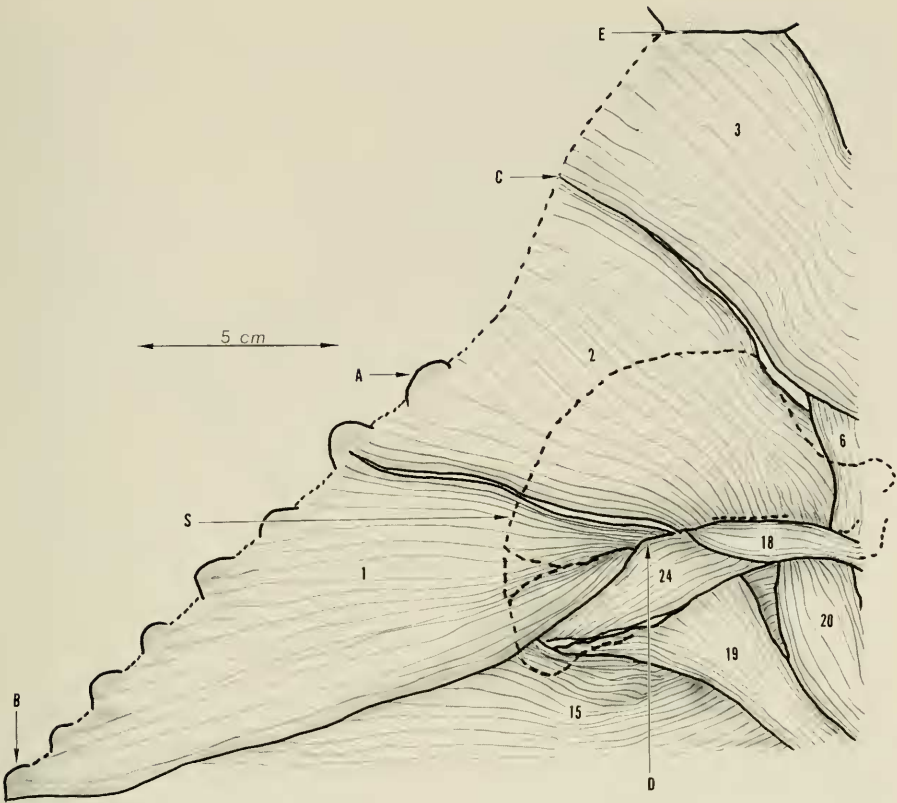


FIGURE 7. Lateral view of the right side of the trunk to show the superficial trapezius muscle complex, which consists of three muscles, the spinothrapezius (1), the acromiorthrapezius (2), and the clavorthrapezius (3). These muscles are vago-accessory, presumably having migrated posteriorly from the pharyngeal area. Together they form a broad dorsal sheet of muscle suspending the pectoral girdle and the forelimb from the middorsal line of the body. The scapula is outlined to show its relationship to the musculature. Key: 1, spinothrapezius; 2, acromiorthrapezius; 3, clavorthrapezius; 6, omotracheal (levator scapulae ventralis); 15, latissimus dorsi; 18, spinodeltoideus; 19, dorsoepitrachlearis; 20, triceps brachii caput longus; 24, infraspinatus; A, spinous process of first dorsal vertebra; B, spinous process of eighth dorsal vertebra; C, middorsal line-cervical area; D, site of tuberosity on spine of scapula; E, lambdoid ridge of skull; S, outline of scapula.

the clavorthrapezius, forms a broad superficial muscle sheath joining the axial skeleton to the scapula and forelimb. The muscle is thin and triangular in shape with the base along the middorsal line.

ORIGIN. Arising by fleshy fibers along the middorsal line and spinous processes from T-2 to T-8, the muscle triangulates toward the tuberosity of the scapular spine, where a short, flat tendon develops.

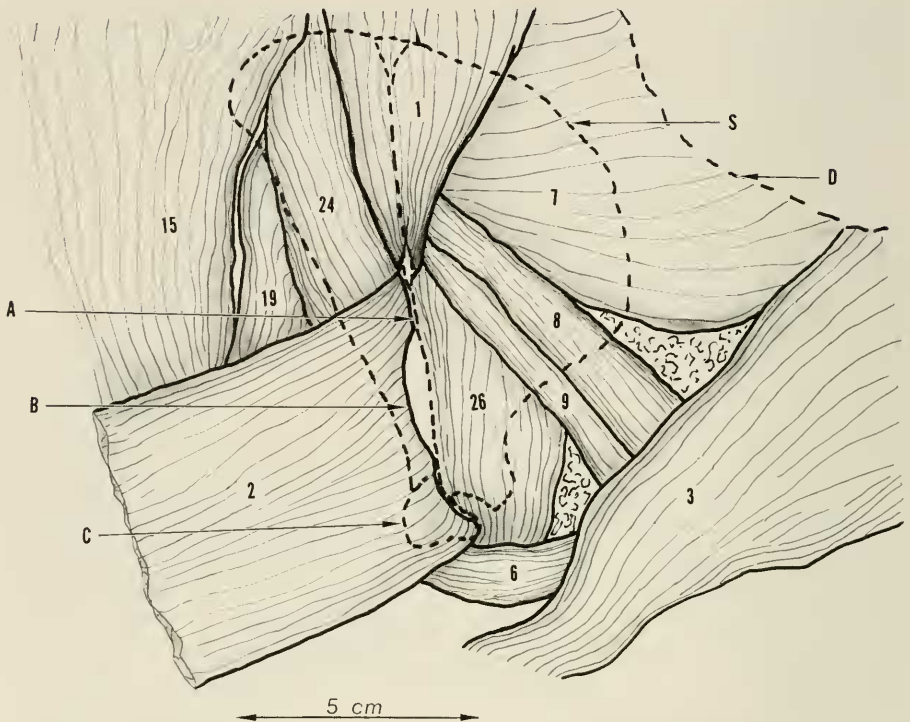


FIGURE 8. Lateral view of the right scapular area. The acromiotrapezius muscle (2) has been detached from its origin and reflected downward and posteriorly to show the detail of its insertion on the scapular spine and acromion process. Note the unattached raphe area (B). The deeper rhomboid muscles, (7), (8), (9), lying beneath the acromiotrapezius muscle are now exposed. Key: 1, spinotrapezius; 2, acromiotrapezius; 3, clavotrapezius; 6, omotracheal (levator scapulae ventralis); 7, rhomboideus major; 8, rhomboideus capitis; 9, rhomboideus profundus; 15, latissimus dorsi; 19, dorsoepitrichlearis; 24, infraspinatus; 26, supraspinatus; A, scapula, spine; B, raphe—unattached to spine of scapula; C, scapula, acromion process; D, middorsal line, cervical area; S, outline of scapula.

INSERTION. The tendon inserts on the tuberosity of the spine of the scapula along the anterior and distal surface.

ACTION. The principal action is to support the scapula and forelimb and move these structures toward the middorsal line.

2. Acromiotrapezius.

This is the central muscle of the trapezius muscle complex being situated between the spinotrapezius posteriorly and the clavotrapezius anteriorly. The muscle is thin and broad, and rhomboid in shape.

ORIGIN. Arising by fleshy fibers from a broad base along the middorsal

line extending from the midcervical area anteriorly to the spinous process of T-2 posteriorly. The muscle passes sheetlike toward the spine of the scapula. Here, the muscle fibers end in a crescent-shaped tendinous raphe in the central area and in short tendon fibers at the proximal end and fleshy fibers at the distal end.

INSERTION. The proximal tendon fibers insert on the tuberosity of the spine of the scapula just distal to the tendon of the spinotrapezius. The distal fleshy fibers insert on the full length of the acromion process of the scapula. The tendinous raphe spans between the two insertions and is unattached to the spine of the scapula, although paralleling it. The distal insertion is crossed superficially by the omotracheon muscle. The tendinous raphe gives origin to the spinodeltoideus muscle.

ACTION. This muscle assists in the support of the scapula and forelimb from the axial skeleton and can assist in rotating the scapula counterclockwise.

3. *Clavotrapezius.*

The anterior muscle of the trapezius muscle complex is also thin and broad and closely associated along its posterior border with the acromiotrapezius. The muscle is somewhat triangular in shape with a broad base dorsally.

ORIGIN. The muscle arises by fleshy fibers from the middorsal line adjacent to the origin of the spinotrapezius in the cervical area. The origin extends anteriorly the length of the remaining cervical area to reach the skull at the external occipital crest. The origin then continues laterally along the lambdoid ridge of the skull approximately one-third the distance to the jugular process. From their origin the muscle fibers pass ventrally toward the shoulder, at which point the muscle divides into an anterior one-third and posterior two-thirds.

INSERTION. The anterior one-third of the muscle continues toward the clavicular area inserting into the deep fascia at this site since there is no clavicle. The posterior two-thirds of the muscle divides about equally into two parts. The anterior portion joins with a remaining portion of the cleidomastoid muscle at this level to continue distally and eventually reaches the ulna. The posterior portion joins with the muscle fibers from the cleidomastoid muscle to form the clavobrachialis muscle, which in turn inserts more distally along the pectoral ridge of the humerus.

ACTION. With this somewhat complicated insertion the muscle acts, in addition to supporting the pectoral girdle and drawing it upwards and forward, to assist in flexion of both the shoulder and elbow.

4. *Cleidomastoideus.*

This long, thick, straplike muscle joins the skull to the upper extremity.

ORIGIN. Arising by fleshy fibers from the anterior and inferior surface of

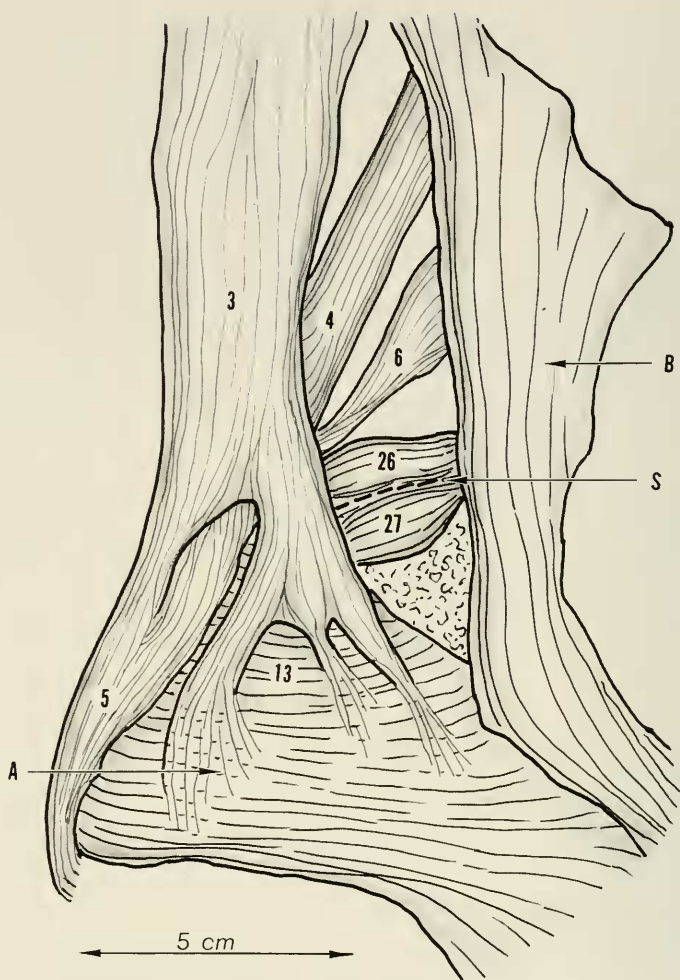


FIGURE 9. Anterolateral view of the right shoulder. The clavotrapezius—cleidomastoideus—and clavobrachialis complex. This somewhat complex muscle arrangement, occurring over the point of the shoulder, is depicted in figures 9, 10, and 11. The essential feature is an interchange of muscle fibers between the clavotrapezius (3) and the cleidomastoideus (4) resulting in the formation of the clavobrachialis muscle (5).

This view shows a division of the clavotrapezius (3) into an anterior one-third which spreads out to insert into the pectoral fascia, and a posterior two-thirds being joined by fibers of the cleidomastoideus (4) to form the clavobrachialis muscle (5). Not shown in this plate is the continuation of the cleidomastoideus (4) and its being joined by muscle fibers from the clavotrapezius (3); see figure 11 for this detail. Key: 3, clavotrapezius; 4, cleidomastoideus; 5, clavobrachialis; 6, omotrachean (levator scapulae ventralis); 13, pectoralis major; 26, supraspinatus; 27, subcapularis; A, pectoral fascia; B, sternomastoideus muscle; S, scapula, superior border.

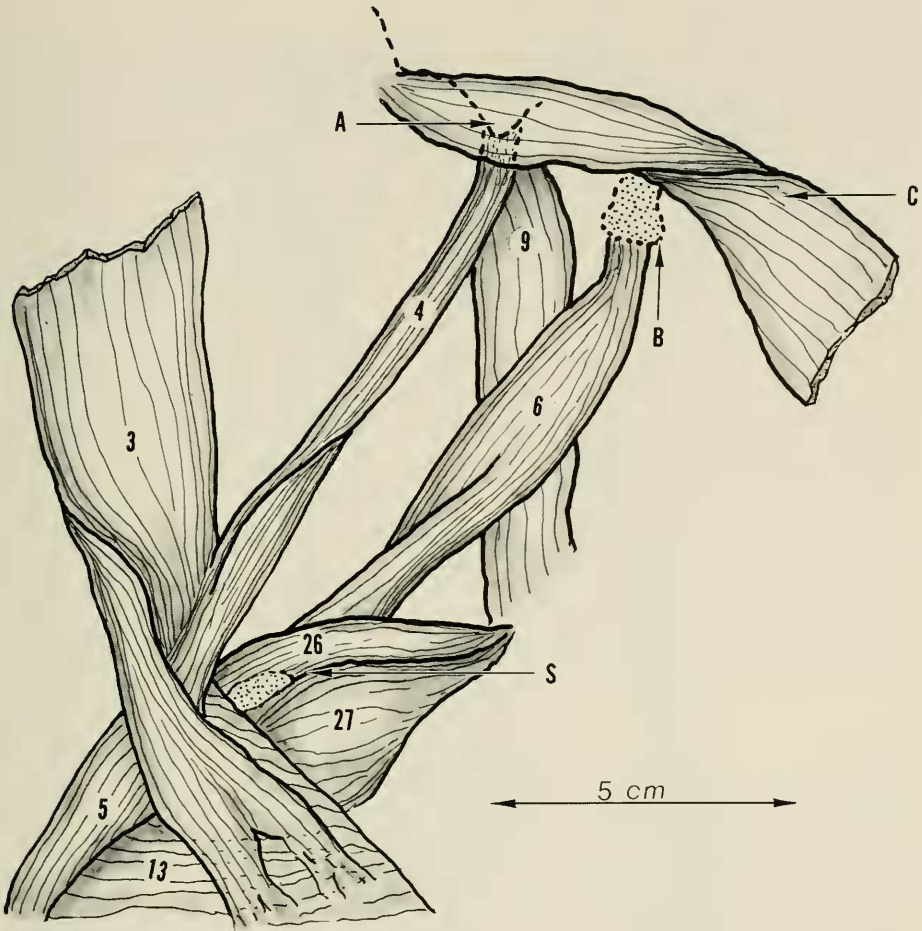


FIGURE 10. Anterolateral view of the right shoulder area identical to figure 8, except that the clavotrapezius muscle (3) has been detached from its origin and reflected laterally and posteriorly. The sternomastoideus muscle (C) has been reflected anteriorly. The muscle interchange to form the clavobrachialis (5) is again shown. Not shown (as in figure 9) is the continuation of the cleidomastoideus muscle (4). Key: 3, clavotrapezius; 4, cleidomastoideus; 5, clavobrachialis; 6, omotrachlean (levator scapulae ventralis); 9, rhomboideus profundus; 13, pectoralis major; 26, supraspinatus; 27, subscapularis; A, mastoid process of the skull; B, transverse process of the first cervical vertebra; C, sternomastoideus muscle; S, scapula, superior margin.

the mastoid process of the skull, the muscle passes in uniform diameter under the clavotrapezius and over the omotrachleon toward the shoulder at which point the muscle splits into a posterior one-fourth and an anterior three-fourths.

INSERTION. The posterior one-fourth joins with the muscle fibers from

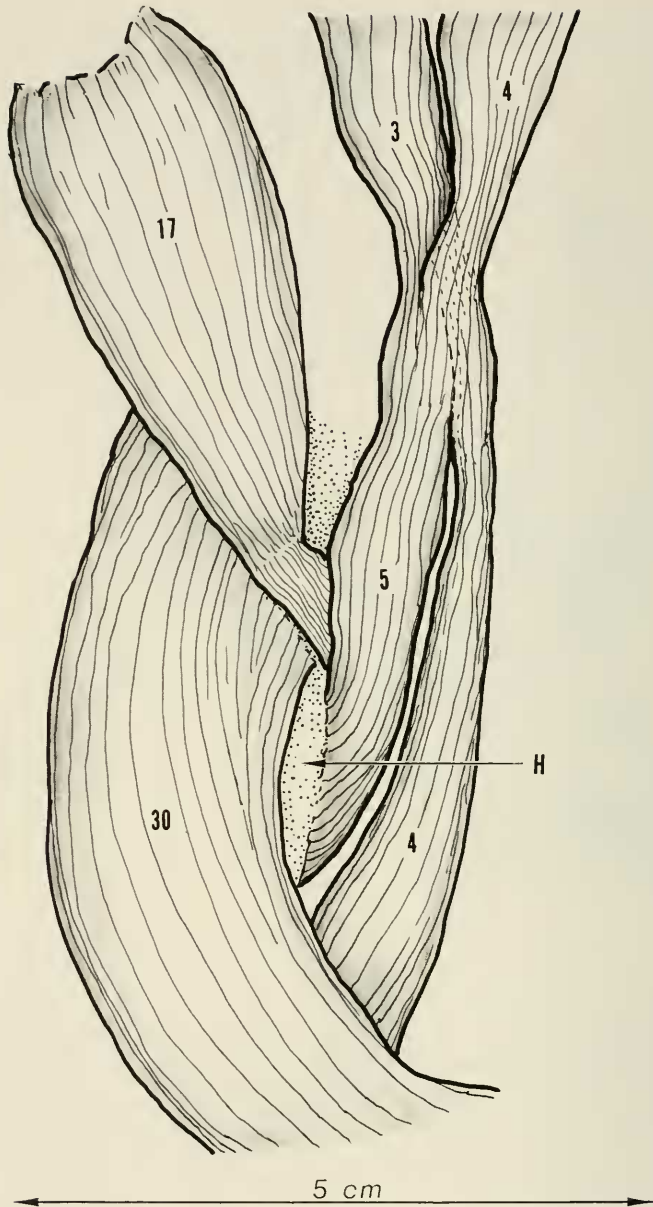


FIGURE 11. An enlarged view of the right shoulder area and upper humerus to show the continuation of the cleidomastoideus muscle (4) and its receiving of muscle fibers from the clavotrapezius (3) (depicted by dotted line). Also shown is the insertion of the clavobrachialis (5) and the acromiodeltoideus (17). Key: 3, clavotrapezius; 4, cleidomastoideus; 5, clavobrachialis; 17, acromiodeltoideus; 30, brachioradialis; H, humerus.

the clavotrapezius to form the clavobrachialis muscle. The anterior three-fourths joins with the remaining muscle fibers of the clavotrapezius. Thus reinforced, this combined muscle continues distally into the anterior cubital area of the elbow where it joins with the pectoantebrachialis muscle which, in turn, inserts into the ulna.

ACTION. With this somewhat complicated insertion it would be difficult to analyze the specific action of this muscle. From its position the muscle could assist in both flexion of the elbow and shoulder and drawing of the forelimb forward and dorsally.

5. *Clavobrachialis.*

This is a rather small flat muscle passing over the shoulder area.

ORIGIN. This muscle is made up of fibers from the clavotrapezius and the cleidomastoideus as described in the description of each. The newly formed muscle converges to a longitudinal linear configuration.

INSERTION. The muscle fibers insert into the humerus along the pectoral ridge at its junction with the deltoid ridge. The insertion is adjacent to and just posterior to the insertion of the pectoralis major muscle and just distal to the insertion of the spinodeltoideus and acromiodeltoideus muscles.

ACTION. This small muscle, by virtue of its position, could assist in abduction and flexion of the humerus.

6. *Omotracheon (levator scapulae ventralis).*

This is a long, flat, ribbonlike muscle connecting the scapula to the spine.

ORIGIN. This muscle arises by fleshy fibers from the anteromedial surface of the transverse process of the first cervical vertebra. At its point of origin it overlies the origin of the rhomboideus profundus muscle. The muscle passes obliquely posteriorly across the neck toward the acromion process of the scapula.

INSERTION. About one-fourth of the fibers split off anteriorly just before reaching the acromion process of the scapula. These fibers join the panniculus carnosus muscle of the forelimb. The remaining fibers insert into the posterior border of the acromion process of the scapula.

ACTION. This muscle serves to support the scapula and rotate it counter-clockwise.

7. *Rhomboideus major.*

This thin, flat, triangular muscle lies beneath the trapezius muscle complex and connects the scapula with the axial skeleton.

ORIGIN. Fleshy fibers arise from the middorsal line of the cervical area starting just posterior to the external occipital crest and continue posteriorly the full length of the cervical spine into the thoracic area to terminate at the

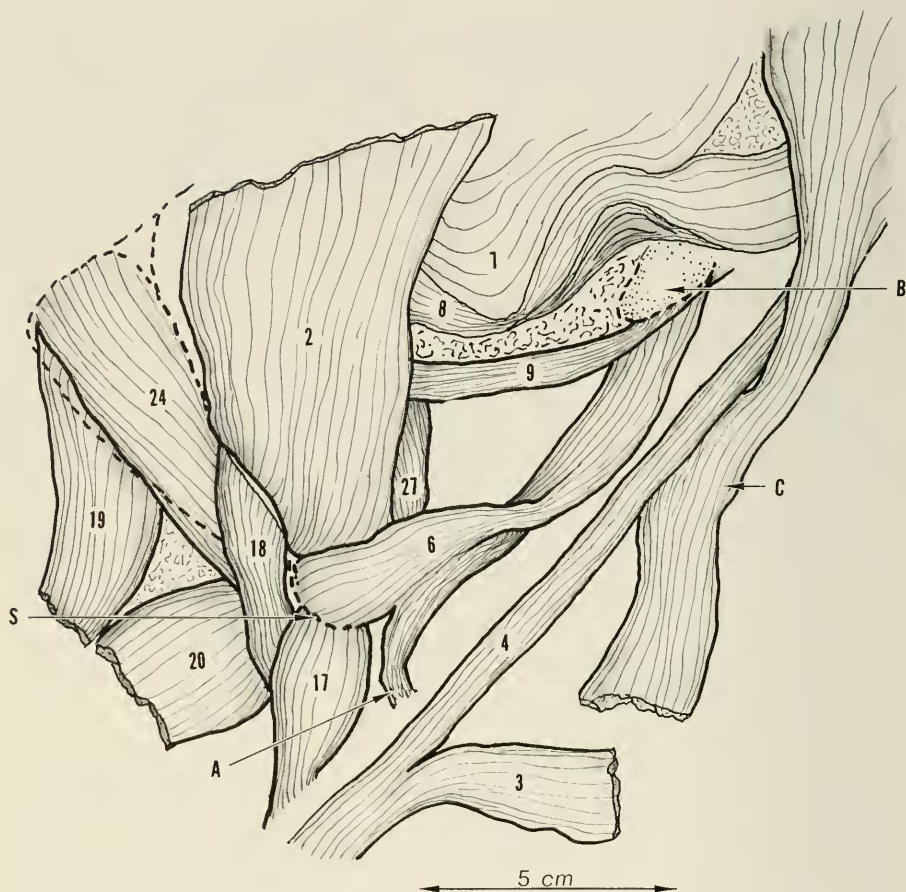


FIGURE 12. Lateral view of the right shoulder and neck area to show origin and insertion of omotracheal muscle (levator scapulae ventralis) (6) and its relation to the other muscles in the area. The rhomboideus major (7) and the rhomboideus capitis (8) have been reflected dorsally. The clavotrapezius (3) detached at its origin, is reflected anteriorly for clear exposure of the underlying musculature. The spinotrapezius has been removed. Key: 2, acromiotrapezius; 3, clavotrapezius; 4, cleidomastoideus; 6, omotracheal (levator scapulae ventralis); 7, rhomboideus major; 8, rhomboideus capitis; 9, rhomboideus profundus; 17, acromiodeltoideus; 18, spinodeltoideus; 19, dorsoepitrochlearis; 20, triceps brachii caput longus; 24, infraspinatus; 27, subscapularis; A, to the panniculus carnosus; B, transverse process of first cervical vertebra; C, sternomastoid muscle; S, scapula, acromion process.

dorsal spine of T-3. From its origin the muscle triangulates toward the posterior portion of the vertebral border of the scapula.

INSERTION. Fleshy and tendinous fibers insert along the vertebral border of the scapula, starting at the inferior angle and extending anteriorly to the origin of the scapular spine. At this point, a tendinous raphe is formed which

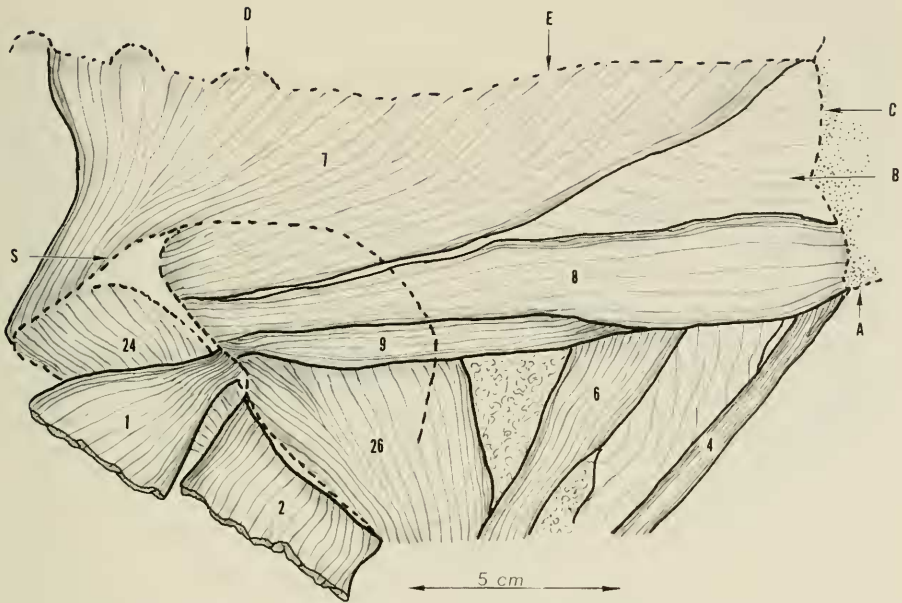


FIGURE 13. Dorsolateral view of right cervical and scapular to show the rhomboid muscle complex. This group of three muscles, the rhomboideus major (7), capitis (8), and profundus (9), form a sheet-like layer beneath the trapezius muscle group. In this plate the spinotrapezius (1) and the acromiotrapezius (2) have been detached at their origins and reflected ventrally. The clavotrapezius has been removed. As noted from their origins and insertions, these three rhomboid muscles act to support the pectoral girdle drawing it forward and rotating it clockwise. Key: 1, spinotrapezius; 2, acromiotrapezius; 4, cleidomastoideus; 6, omotracheal (levator scapulae ventralis); 7, rhomboideus major; 8, rhomboideus capitis; 9, rhomboideus profundus; 24, infraspinatus; 25, supraspinatus; A, mastoid process of skull; B, deep cervical musculature; C, lambdoid ridge of skull; D, spinous process of first dorsal vertebra; E, middorsal line, cervical area; S, outline of scapular.

spans the area of origin of the spine, then joins the remaining fibers to insert along the anterior ridge of origin of the scapular spine. This latter portion overlies and more-or-less joins with the insertion of the rhomboideus capitis.

ACTION. This muscle pulls the scapula forward as in shrugging the shoulder. It can also rotate the scapula clockwise.

8. *Rhomboideus capitis*.

The second of the rhomboideus muscle group is a thin, flat, elongated muscle connecting the skull with the scapula. The muscle parallels to a degree the inferior border of the rhomboideus major and underlies the trapezius musculature in this area.

ORIGIN. Arising by fleshy fibers from the lateral one-third of the lambdoidal

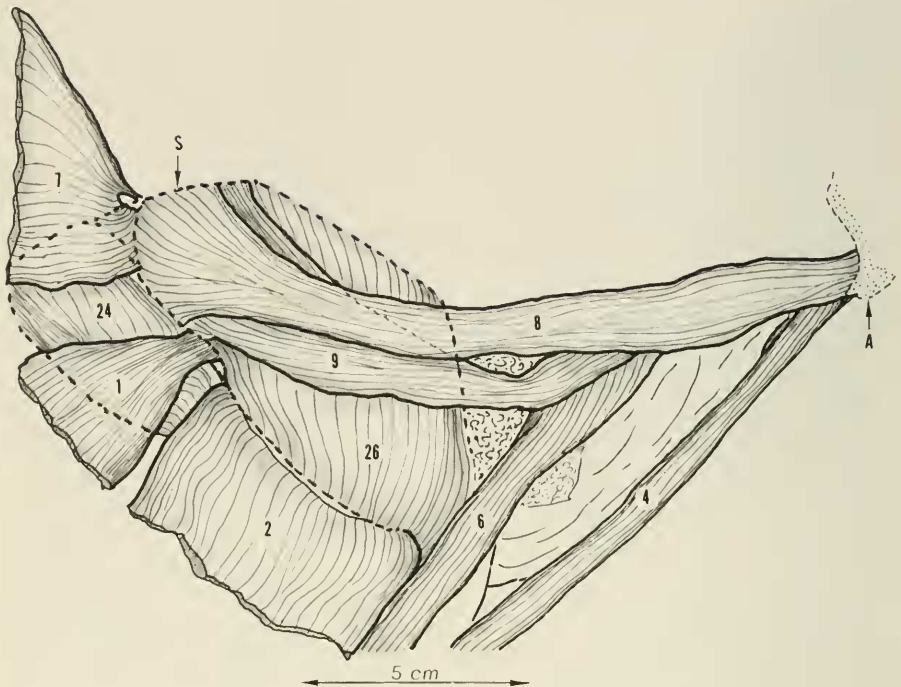


FIGURE 14. Dorsolateral view of cervical and scapular area identical with figure 13 except that the rhomboideus major (7) has been detached from its origin and reflected posteriorly at its insertion. The origin and insertion of the rhomboideus capitis (8) is shown. Key: 1, spinothrapezius—reflected; 2, acromiorthrapezius—reflected; 4, cleidomastoideus; 6, omotrachean; 7, rhomboideus major—reflected; 8, rhomboideus capitis; 9, rhomboideus profundus; 24, infraspinatus; 26, supraspinatus; A, mastoid process of the skull; S, outline of scapula.

crest and the jugular process of the skull, the muscle courses inferiorly to pass over the supraspinatus fossa of the scapula where it widens in a flare-type manner terminating in a thin, flat, tendinous, sheath.

INSERTION. This flat, thin tendon inserts along the spine of the scapula more or less fusing with the tendon of the rhomboideus major but also continues its insertion along the vertebral margin of the scapula superiorly approximately two-thirds of the distance to the first angulation of this margin.

ACTION. The muscle draws the scapula forward and acts to rotate the scapula clockwise.

9. *Rhomboideus profundus.*

The third and deepest of the rhomboid muscles underlies, for the most part, the rhomboideus capitis and connects the spine to the scapula.

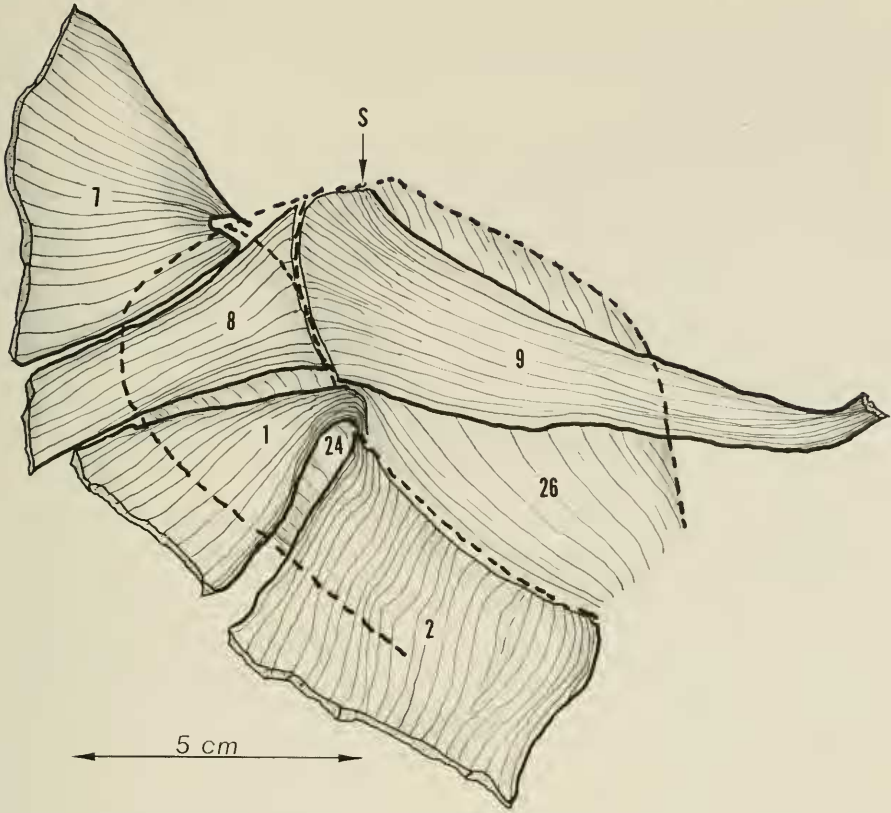


FIGURE 15. Lateral view of right scapula. The rhomboideus major (7) and the rhomboideus capitis (8) have been reflected posteriorly to show the detail of insertion of the rhomboideus profundus (9) on the scapula. Again, the spinothrapezius (1) and the acromiathrapezius (2) have been reflected as in the previous plate. Key: 1, spinothrapezius—reflected; 2, acromiathrapezius—reflected; 7, rhomboideus major—reflected; 8, rhomboideus capitis—reflected; 9, rhomboideus profundus; 24, infraspinatus; 26, supraspinatus; S, outline of scapula.

ORIGIN. This muscle arises by fleshy fibers from the inferior surface of the transverse process of C-1 vertebra overlying the origin of the omotracheleon muscle. From this point the strap-type muscle passes obliquely inferiorly to underlie the rhomboideus capitis as it reaches the scapula area. Near its insertion the muscle spans out ending in a thin tendinous sheath in a manner similar to the rhomboideus capitis.

INSERTION. The tendon of the rhomboideus profundus inserts with that of the rhomboideus capitis but extends more superiorly along the vertebral margin of the scapula to the first angulation of the vertebral border.

ACTION. This muscle's action is the same as that of the rhomboideus capitis, drawing the scapula forward and rotating it clockwise.

10. *Serratus magnus.*

This large, flat, interdigitated muscle connects the rib cage with the vertebral margin of the scapula, and is the posterior portion of a common suspensory sheet of muscle which includes superiorly the levator anguli scapulae. The muscle is best observed as the vertebral margin of the scapula is spread out from the rib cage.

ORIGIN. Arising by fleshy digitations from ribs 1 to 6; starting on rib 1 near the spine the origin continues in an oblique line to rib 6 at about the level of the midlateral line of the chest. The muscle triangulates from its origin toward the vertebral margin of the scapula and, in doing so, the digitation is joined into a flat muscular sheath, the superior margin of which becomes continuous with the levator anguli scapulae.

INSERTION. The serratus magnus portion of this muscle sheath inserts on the vertebral margin of the scapula starting at the inferior angle and extending superiorly to the level of origin of the scapular spine where it joins the levator anguli scapulae. The insertion is deep to that of the rhomboideus major.

ACTION. This muscle acts to hold the scapula against the chest wall and serves to suspend the trunk in weight bearing. It can also move the scapula in the line of its fibers.

11. *Levator anguli scapulae.*

This muscle is, in effect, the superior continuation of the serratus magnus and connects the cervical spine to the scapula.

ORIGIN. Fleshy fibers arise from the transverse processes and intervening fascia of C-3 to C-7. A sheet of muscle is formed which triangulates toward the vertebral margin of the scapula. The inferior border approximates the superior border of the serratus magnus distally to form a common muscle.

INSERTION. The levator anguli scapulae portion of the muscle sheath inserts superiorly to the serratus magnus in a similar manner along the vertebral margin of the scapula from the origin of the scapular spine halfway to the superior angle of the scapula.

ACTION. In view of the muscle's more dorsal origin, the action is to suspend the scapula and rotate the scapula clockwise. It also assists the serratus magnus muscle in holding the vertebral margin of the scapula to the chest wall.

12. *Pectoantebrachialis.*

This muscle is the most superficial of the pectoral muscle group. It is a large, strong, triangular muscle connecting the trunk to the forearm.

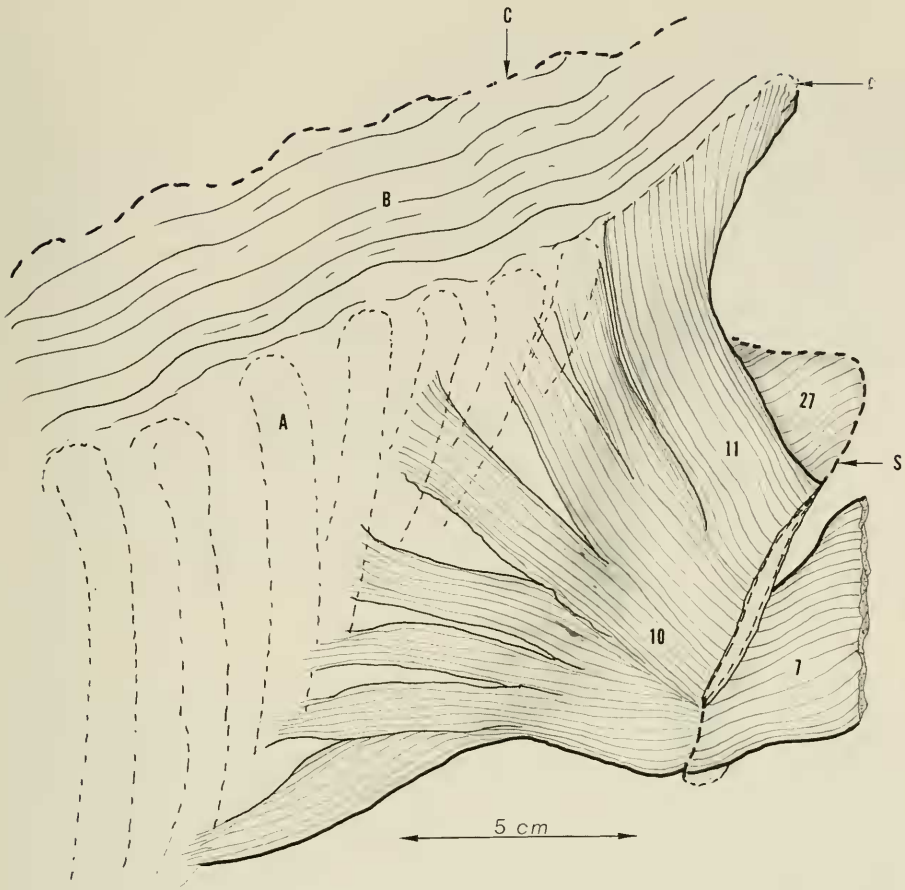


FIGURE 16. Dorsal view of right-shoulder area. The trapezius muscles have been removed. The rhomboideus major (7) is shown reflected outward from the vertebral margin of the scapula. The scapula has been spread outward from the body to disclose the serratus magnus (10) and the levator anguli scapulae (11) muscles. These broad, flat but thick and strong muscles act as a sling support for the trunk between the forelimbs. The two muscles form a common and continuous muscle sheath, their division being based on the site of origin, the levator anguli scapulae (11) from the cervical area, serratus magnus (10) from the rib cage. Key: 7, rhomboideus major—reflected; 10, serratus magnus; 11, levator anguli scapulae; 27, subscapularis; A, fifth rib; B, deep cervical musculature; C, middorsal line cervical area; D, transverse process of third cervical vertebra; S, scapula, vertebral margin.

ORIGIN. Fleshy fibers arise from the superior part of the sternum starting at the upper border of the manubrium and reaching to between ribs 1 and 2. The muscle then courses obliquely inferiorly over the pectoral musculature toward the anterior cubital area where the muscle converges and, joined by

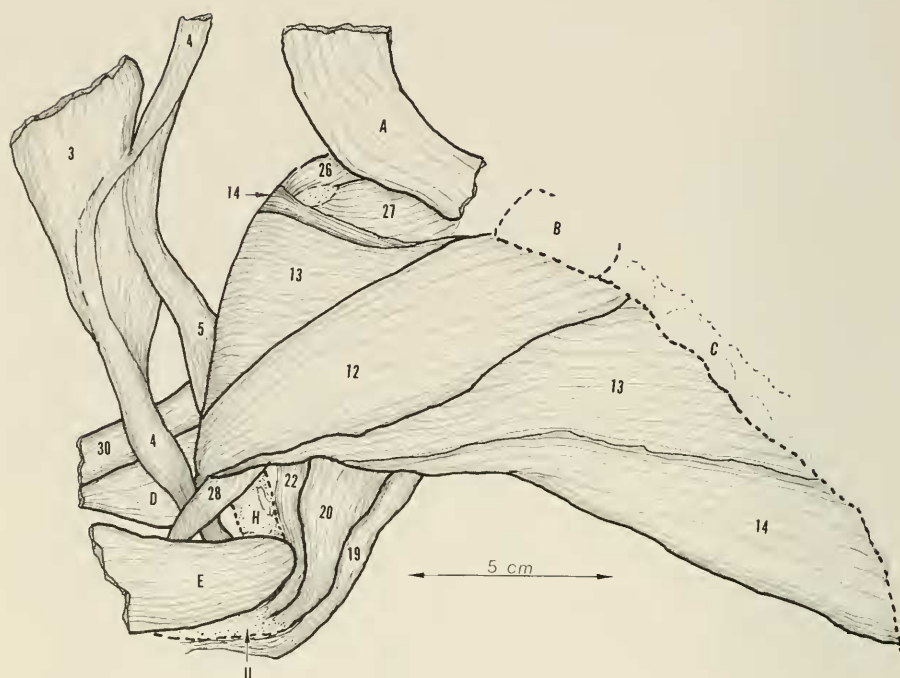


FIGURE 17. Anterior view of the right humerus and upper chest with the forelimb rotated externally. The cleidomastoideus (4) and clavotrapezius (3) are reflected laterally. The sternomastoid muscle (A) is detached at its insertion and reflected superiorly. The pectoral muscle complex is thus revealed. This complex consists of three flat, thick, and strong muscles arising from the anterior upper chest, connecting the trunk to the upper extremities. The most superficial is the pectoantibrachialis (12) which overlies the pectoralis major (13), which in turn overlies the pectoralis minor (14). This strong muscle group flexes and internally rotates the humerus. In addition, action of the pectoantibrachialis (12) is to assist in flexion of the elbow. Further detail of the relationship of these three muscles is shown in figures 18, 19, and 20. Key: 3, clavotrapezius—reflected; 4, cleidomastoideus—reflected; 5, clavobrachialis—reflected; 12, pectoantibrachialis; 13, pectoralis major; 14, pectoralis minor; 19, dorsoepitrochlearis; 20, triceps brachii caput longus; 22, triceps brachii caput medialis; 26, supraspinatus; 28, biceps brachii; 30, brachioradialis; A, sternocleidomastoid muscle—reflected; B, sternum, manubrium; C, sternum, corpus; D, extensor muscles of the forearm; E, flexor muscles of the forearm; H, humerus; U, ulna.

fibers from both the cleidomastoideus laterally and pectoralis major medially, forms a strong tendon.

INSERTION. Passing deep to the tendon of insertion of the biceps, the heavy tendon of the pectoantibrachialis inserts on the medial ridge of the ulna at the conoid process just distal to the joint surface.

ACTION. Strong flexion of the elbow is accomplished plus assistance in flexion of the humerus.

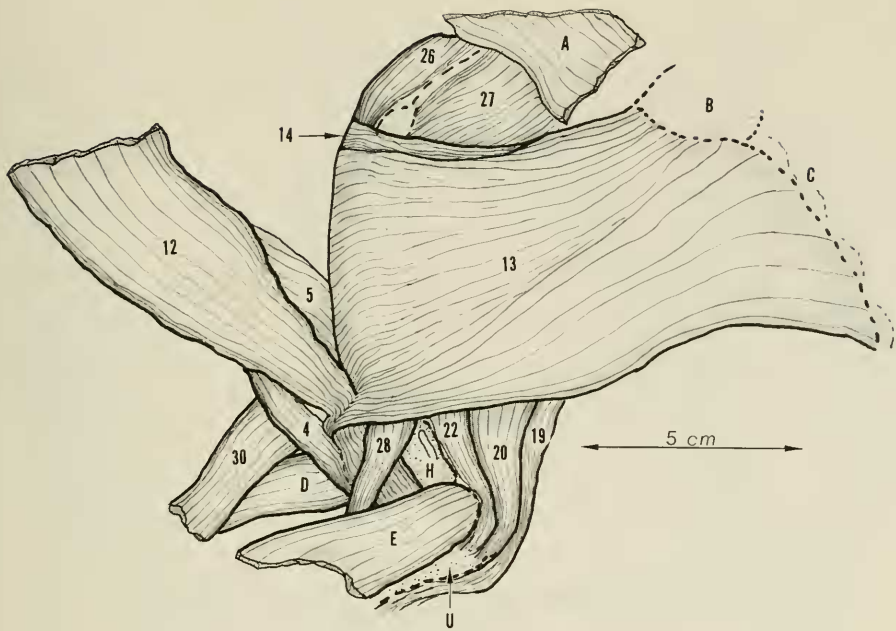


FIGURE 18. Anterior view of the right upper chest and humerus with the forelimb rotated externally. This is essentially the same view as figure 17 but with the pectoantebrachialis (12) reflected laterally to show the pectoralis major (13) and the lower fibers of the muscle joining with the pectoantebrachialis (12) which in turn joins the cleidomastoideus (4) for common insertion into the proximal ulna. The lower part of the pectoralis minor has been omitted in this drawing. Key: 4, cleidomastoideus; 5, clavobrachialis; 12, pectoantebrachialis—reflected; 13, pectoralis major; 14, pectoralis minor; 19, dorsoepitrochlearis; 20, triceps brachii caput longus; 22, triceps brachii caput medialis; 26, supraspinatus; 28, biceps brachii; 30, brachioradialis; A, sternocleidomastoid—reflected; B, sternum, manubrium; C, sternum, corpus; D, extensor muscles of forearm; E, flexor muscles of forearm; H, humerus; U, ulna.

13. Pectoralis major.

This strong, broad, rhomboid muscle of the pectoral group underlies the pectoantebrachialis and connects the sternum to the humerus. The muscle is heaviest superiorly.

ORIGIN. There is a continuous origin of fleshy fibers from the top of the manubrium to the fourth rib level inferiorly. This forms the base of the muscle which then continues transversely as a broad sheet to the humerus. In so doing, the muscle overlies the pectoralis minor and bridges the anterior chest. Short thin tendinous fibers develop on the underside as the humerus is approached.

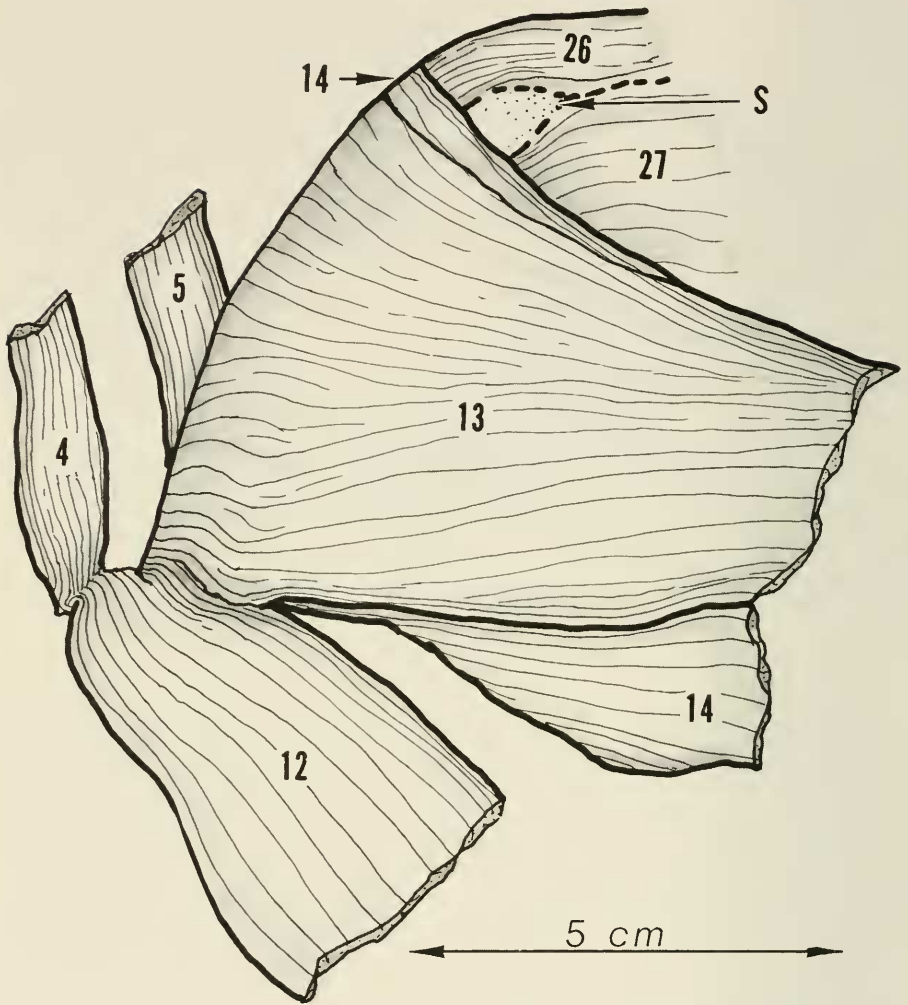


FIGURE 19. An anterior view of the right shoulder and upper arm musculature in a limited area. The pectoantibrachialis (12) has been detached from its origin and reflected inferiorly to show its contribution of muscle fibers to the pectoralis major (13) near its distal insertion on the humerus, and also the joining of the cleidomastoideus (4) with the pectoantibrachialis (12) to form a common tendon. Key: 4, cleidomastoideus; 5, clavobrachialis; 12, pectoantibrachialis; 13, pectoralis major; 14, pectoralis minor; 26, supraspinatus; 27, subscapularis; S, scapula, supraglenoid area of superior border.

INSERTION. The insertion of this muscle extends practically the entire length of the humerus, starting superiorly at the greater tuberosity at the margin of insertion of the supraspinatus tendon and extending distally along the lateral side of the pectoral ridge and humeral crest to the cubital fossa area.

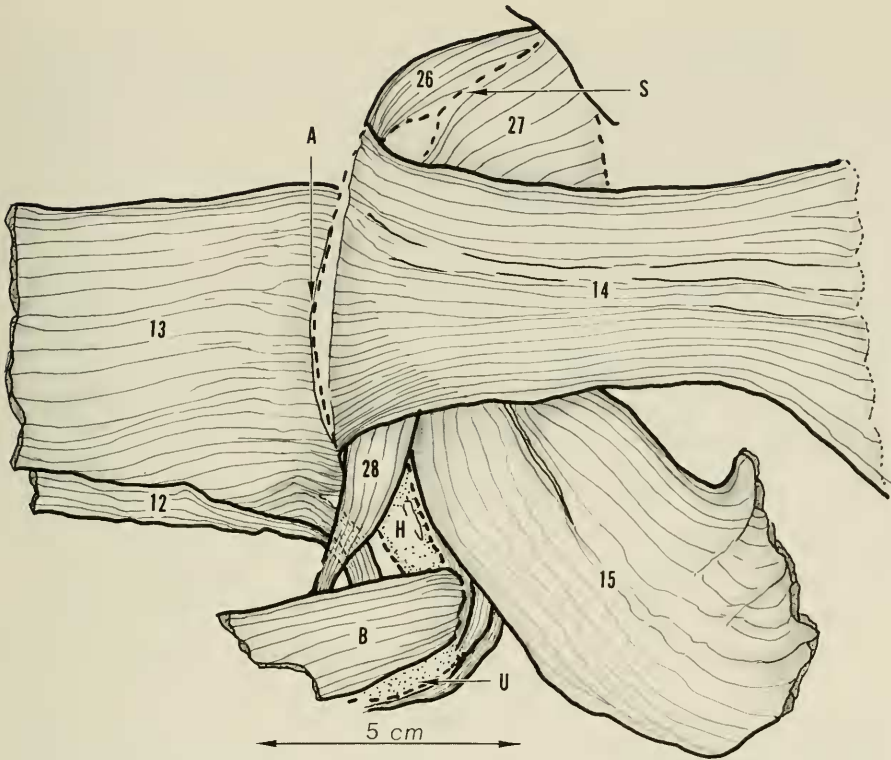


FIGURE 20. Anterior view of right shoulder area with the forelimb adducted and externally rotated. The pectoantebrachialis (12) and the pectoralis major (13) have been detached from their origins and reflected laterally, thus exposing the insertion of the underlying pectoralis minor (14). With adduction of the forelimb the latissimus dorsi (15) comes into view and overlies the triceps muscle group. Note raphe-type insertion of the upper part of the pectoralis major (13). Also shown are the pectoralis major (13) fibers joining the pectoantebrachialis (12). Key: 12, pectoantebrachialis; 13, pectoralis major; 14, pectoralis minor; 15, latissimus dorsi; 26, supraspinatus; 27, subscapularis; 28, biceps brachii; A, raphe-type insertion of pectoralis major; B, forearm flexor musculature; H, humerus; S, scapula, superior margin; U, ulna.

At the upper end, a tendinous raphe is present, and at the lower end some fleshy and tendinous fibers join the pectoantebrachialis muscle.

ACTION. This muscle is a strong flexor and internal rotator of the humerus, and it also assists in adduction of the forelimb.

14. Pectoralis minor.

This deepest muscle of the pectoral group underlies the pectoralis major and joins the trunk to the humerus.

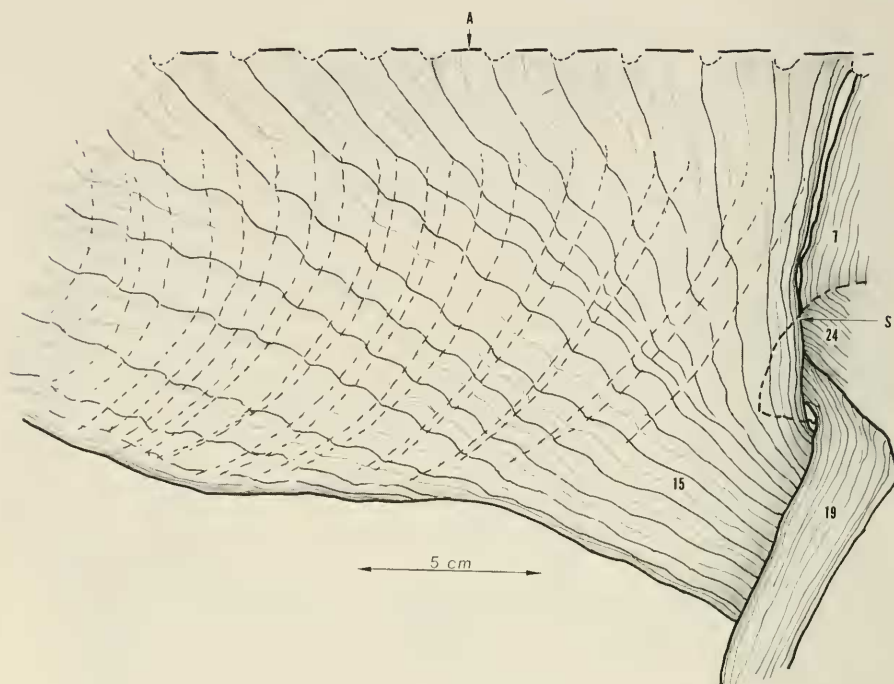


FIGURE 21. Lateral view of right thoracic and shoulder area to show origin of large and strong latissimus dorsi (15) muscle from the trunk, and its relation to the scapula and adjacent musculature. The spinotrapezius muscle which overlies the dorsal and anterior area of the latissimus dorsi (15) has been removed. Key: 7, rhomboideus major; 15, latissimus dorsi; 19, dorsoepitrochlearis; 24, infraspinatus; A, spinous process of eighth dorsal vertebra; S, outline of scapula.

ORIGIN. Arising by fleshy fibers from the border of the sternum, rib levels 2 to 7, this thin flat rectangular muscle courses toward the humerus under the pectoralis major and over the biceps muscle. There is a tendency towards clefting of the muscle in its upper part between ribs 2 and 3. Near the humerus a broad thin tendon develops.

INSERTION. The tendon inserts on the humerus just medial and parallel to the pectoralis major along the length of the pectoral ridge. The uppermost and more fleshy fibers insert on the greater tuberosity of the humerus just medial to the tendon of insertion of the supraspinatus. At the lower or most distal end the tendon is joined by fleshy and tendinous fibers of the anterior half of the split latissimus dorsi muscle for common insertion.

ACTION. Along with the pectoralis major this muscle flexes, internally rotates, and adducts the humerus.

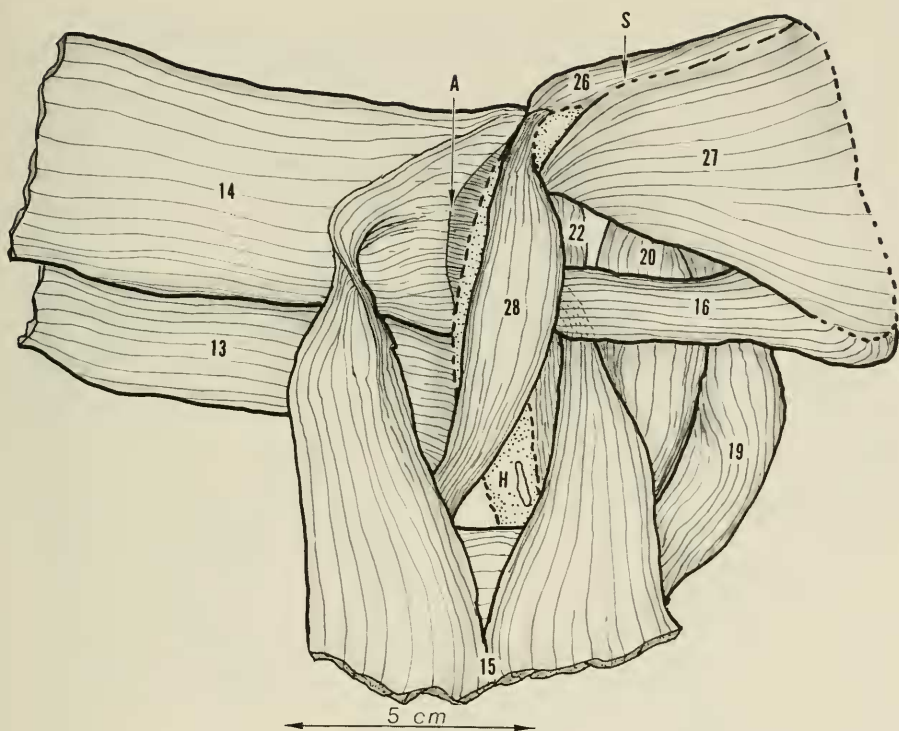


FIGURE 22. Anterior view of the right shoulder and humerus with the upper extremity in external rotation. The pectoral muscles (13) and (14) are reflected laterally exposing the biceps brachii (28) and the teres major (16). The biceps brachii is displaced a bit laterally. The latissimus dorsi (15) is now viewed as the two halves reach their insertion on the humerus. A common tendon of insertion is formed with the teres major and the pectoralis major. Key: 13, pectoralis major; 14, pectoralis minor; 15, latissimus dorsi; 16, teres major; 19, dorsoepitrochlearis; 20, triceps brachii caput longus; 22, triceps brachii caput medialis; 26, supraspinatus; 27, subscapularis; 28, biceps brachii; A, tuberosity of the humerus; H, humerus, S, scapula, superior margin.

15. Latissimus dorsi.

This is a large, flat, strong muscle, triangular in shape, covering most of the thorax from T-3 to T-12 and joining the trunk to the humerus.

ORIGIN. Arising by fleshy fibers from the middorsal line and spinous processes from T-3 to T-9 and then from the lumbar fascia to T-12 level inferiorly and ribs 10 and 11 level midlaterally. This large sheetlike muscle triangulates toward the inferior angle of the scapula, which it crosses to disappear under the dorsoepitrochlearis. At about this point the muscle divides into a dorsal, or proximal, two-fifths and a ventral, or distal, three-fifths, but both divisions con-

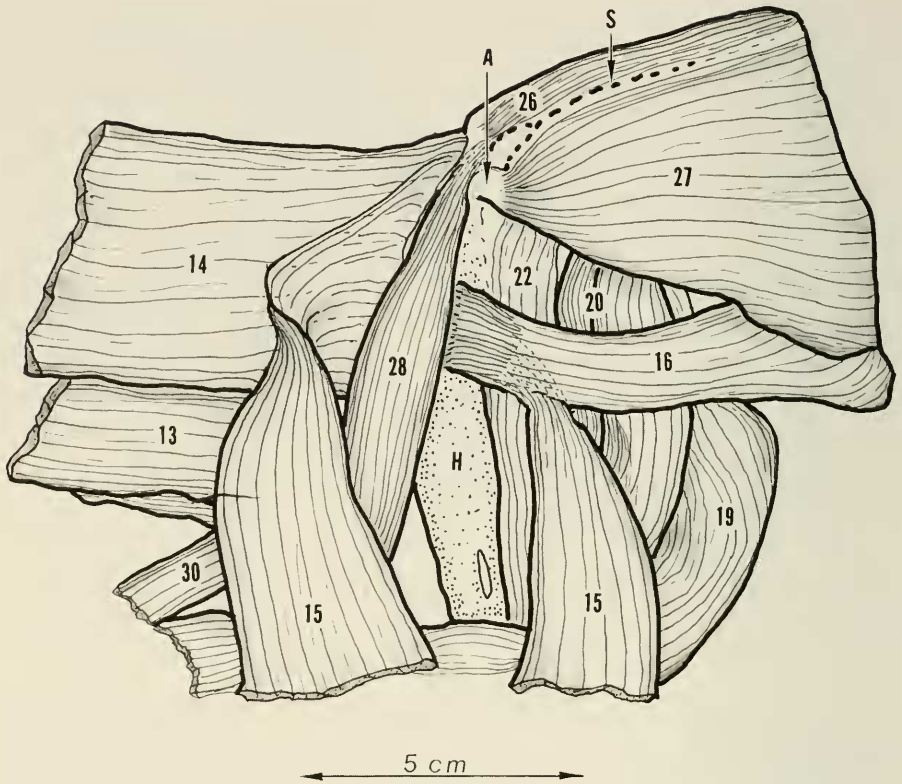


FIGURE 23. Anterior view of the right shoulder and humerus with upper extremity in external rotation. This is essentially the same view as in figure 22 except that the biceps brachii (28) is now displaced medially to disclose the detail of insertion of that portion of the latissimus dorsi (15) which joins the pectoralis minor (14). The pectoral muscles (13) and (14) are again reflected laterally. Key: 13, pectoralis major; 14, pectoralis minor; 15, latissimus dorsi; 16, teres major; 19, dorsoepitrochlearis; 20, triceps brachii caput longus; 22, triceps brachii caput medialis; 26, supraspinatus; 27, subscapularis; 28, biceps brachii; A, tendon fibers begin here; H, humerus; S, scapula, superior border.

tinue under the triceps musculature to gain access to the medial side of the humerus.

INSERTION. At this point, the proximal two-fifths portion narrows and flattens into a tendon which passes between the biceps brachii and the humerus to join that of the teres major for a common insertion on the humerus along the pectoral ridge and just under the insertion of the pectoralis minor. The distal three-fifths of the muscle passes as fleshy fibers anterior to the biceps brachii, then, spreading into flat tendinous fibers, joins the deep side of the tendon of the pectoralis minor for a common insertion with this tendon.

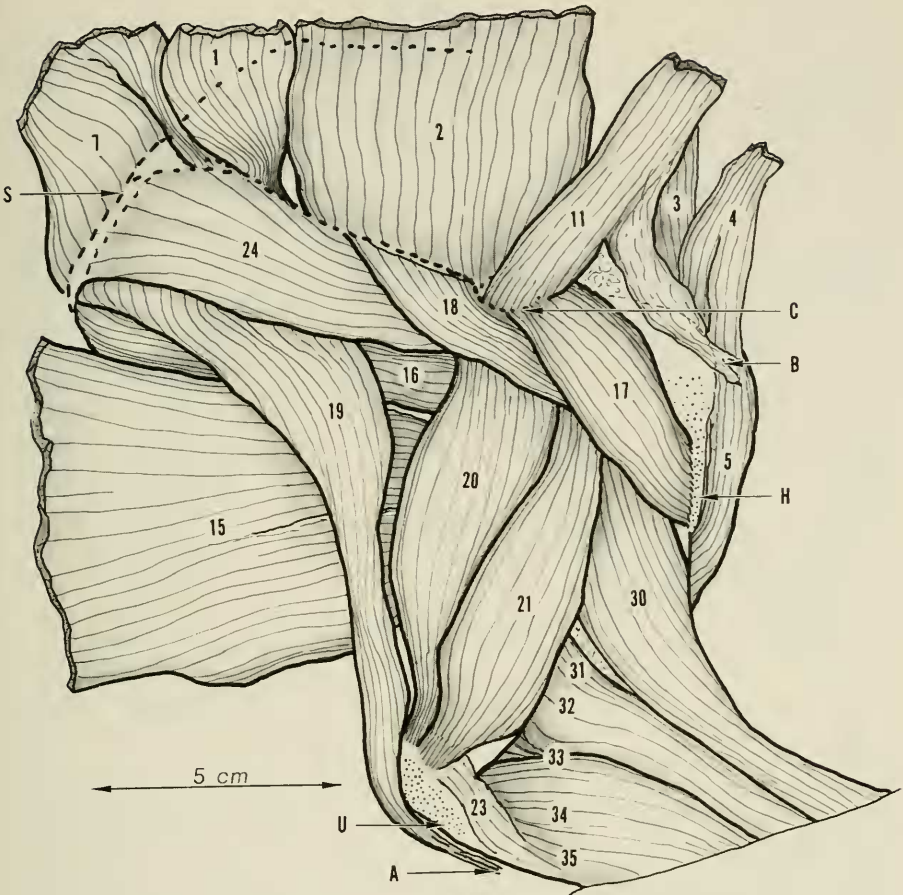


FIGURE 24. Lateral view of the right shoulder and forelimb. The relationship of the acromiodeltoideus (17) and the spinodeltoideus (18) is shown. Also, the insertion of the levator anguli scapulae (11) on the acromion process of the scapula is seen. The clavobrachialis (5) has been reflected anteriorly to show its tendinous insertion on the humerus. The relationship of the other muscles in this lateral view is to be noted. Key: 1, spinotrapezius; 2, acromiotrapezius; 3, clavotrapezius; 4, cleidomastoideus; 5, clavobrachialis; 7, rhomboideus major; 11, levator anguli scapulae; 15, latissimus dorsi; 16, teres major; 17, acromiodeltoideus; 18, spinodeltoideus; 19, dorsoepitrochlearis; 20, triceps brachii caput longus; 21, triceps brachii caput lateralis; 23, anconeus externus; 30, brachioradialis; 31, extensor carpi radialis longus; 32, extensor carpi radialis brevis; 33, extensor digitorum communis; 34, extensor digitorum lateralis; 35, extensor carpi ulneris; A, forearm fascia; B, panniculus carnosus; C, scapula, acromion process; H, humerus; U, ulna; S, scapula, vertebral border.

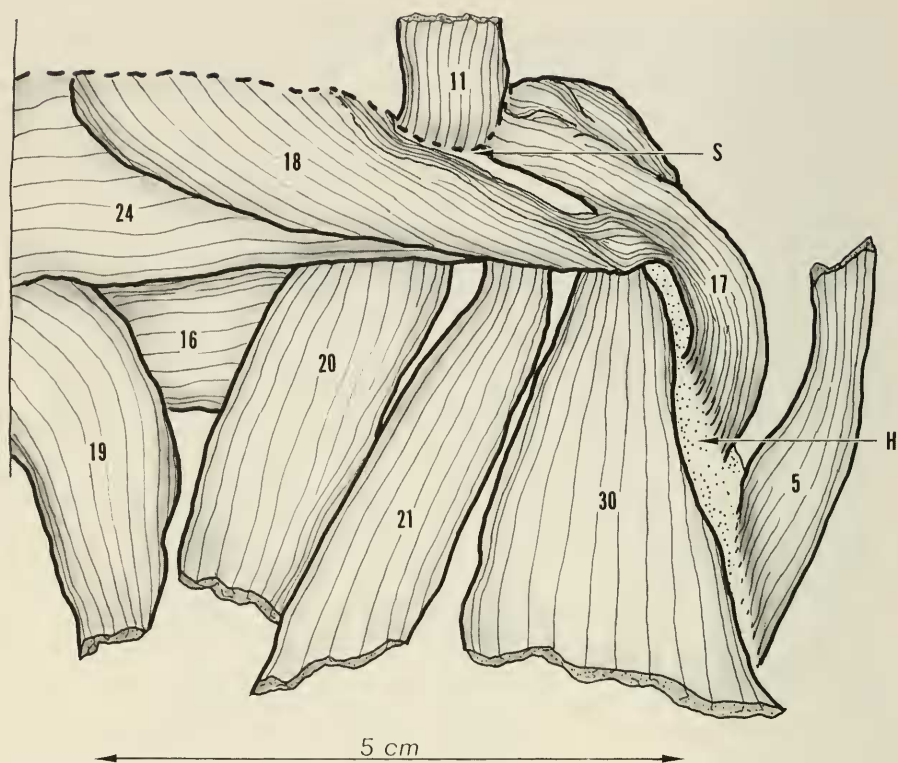


FIGURE 25. Enlarged localized lateral view of the right shoulder area to show detail of spinodeltoideus (18) joining acromiodeltoideus (17) to gain insertion on the humerus. To show this adequately the acromiodeltoideus (17) has been rotated anteriorly, thus exposing the undersurface where the juncture of the two muscles occurs. Key: 5, clavobrachialis; 11, levator anguli scapulae; 16, teres major; 17, acromiodeltoideus; 18, spinodeltoideus; 19, dorsoepitrochlearis; 20, triceps brachii caput longus; 21, triceps brachii caput lateralis; 30, brachioradialis; H, humerus; S, scapula, acromion process.

ACTION. This muscle is a strong extensor and internal rotator of the humerus.

16. *Teres major.*

This short but strong muscle connects the inferior border of the scapula with the humerus.

ORIGIN. Muscle fibers arise from the inferior angle and dorsal one-half of the inferior border of the scapula with some tendinous fibers from the fascia overlying the infraspinatus muscle in this area to form a somewhat cone-shaped muscle paralleling the inferior scapular border passing directly toward the hu-

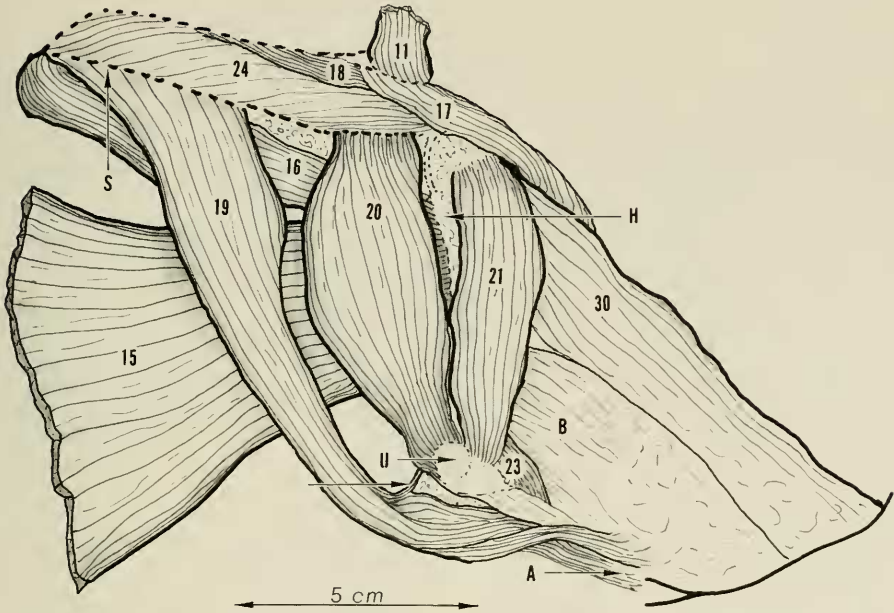


FIGURE 26. The triceps muscle complex is a group of strong muscles arising from the scapula or humerus with insertion on the olecranon process of the ulna to give extension of the elbow joint. The triceps musculature proper consists of the triceps brachii caput longus (20), lateralis (21), and medialis (22). The caput medialis has basically three divisions, having a somewhat complicated configuration and relationship to the caput lateralis (see figure 27). This triad of muscles is reinforced by the large dorsoepitrochlearis (19) which, due to its site of origin from the scapular margin, is responsible for the posterior webbing between the humerus and the scapula. Also, the small anconeus externus (23) is an accessory to this group (see figure 29).

This figure is a posterolateral view of the upper right extremity to show detail of the triceps brachii caput longus (20) and lateralis (21), and the dorsoepitrochlearis (19). Note a few tendon fibers (C) from the dorsoepitrochlearis (19) joining the tendon of the triceps brachii caput longus (20). Key: 11, levator anguli scapulae; 15, latissimus dorsi; 16, teres major; 17, acromiodeltoideus; 18, spinodeltoideus; 19, dorsoepitrochlearis; 20, triceps brachii caput longus; 21, triceps brachii caput lateralis; A, deep fascia of the forearm; B, forearm extensor musculature; C, tendon fibers, from (19) entering tendon of (20); H, humerus; S, outline of scapula, axillary border; U, ulna, olecranon process.

merus. Near the humerus the muscle is joined by muscle and tendon fibers of the superior portion of the latissimus dorsi. A flat strong tendon forms which passes under the biceps brachii.

INSERTION. This tendon now inserts into the humerus on the medial side and nearly parallel to the insertion of the pectoralis minor.

ACTION. Adduction and internal rotation of the humerus is accomplished by this muscle.

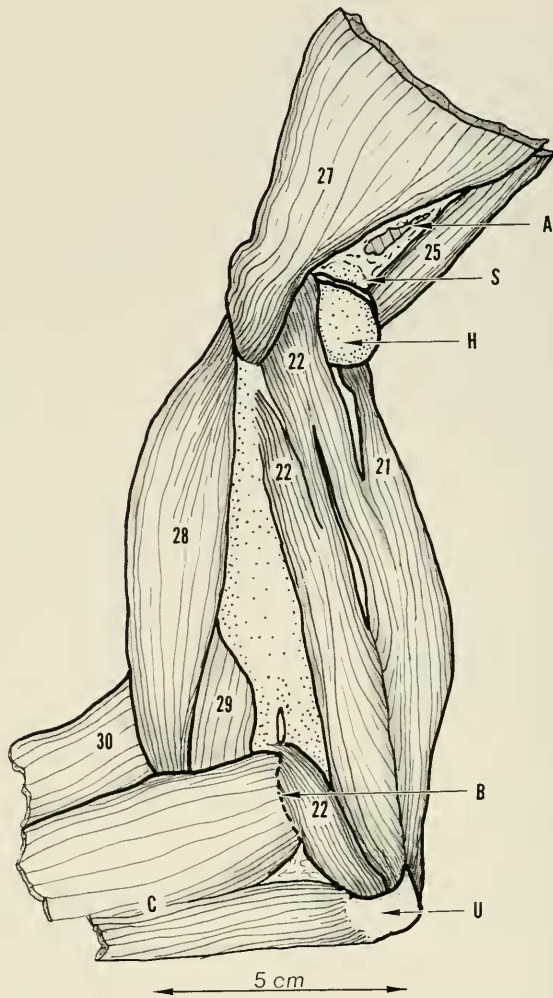


FIGURE 27. Medial view of the right forelimb and shoulder area with the forelimb in full external rotation to show the triceps brachii caput medialis (22), its various parts, and their relationships to each other and to the caput lateralis (21). The caput longus (20) of the triceps has been completely removed. The biceps brachii (28) is displaced anteriorly to visualize the deeper triceps brachii caput medialis (22).

Note the three (22) labels which mark the three parts of the medial head. The upper (22) label is the intermediate part (anconeus internus). The middle (22) label is the long part (anconeus medialis). The lower (22) label is the medial part (anconeus medialis). Key: 21, triceps brachii caput lateralis; 22, triceps brachii caput medialis; 25, teres minor; 27, subscapularis; 28, biceps brachii; 29, brachialis; 30, brachioradialis; A, site of origin of triceps brachialis, caput longus; B, medial epicondylar ridge of humerus; C, forearm flexor musculature; H, humerus, articular surface of head; S, scapula, infraglenoid area; U, ulna, olecranon process.

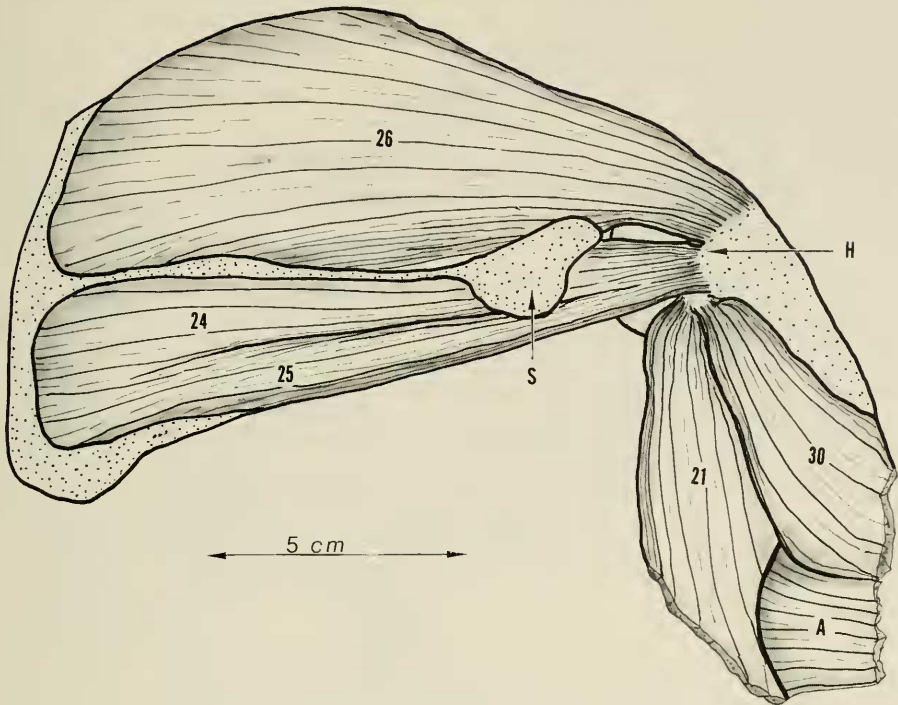


FIGURE 28. The shoulder cuff muscles of the scapula consist of the subscapularis (27), supraspinatus (26), infraspinatus (24), and teres minor (25). All four of these muscles arise from the surface of the scapula and terminate in a tendinous cuff about the shoulder which inserts on the humerus, stabilizing and activating this joint. The tendons are intimately associated with the shoulder joint capsule.

This right lateral view of the scapula and shoulder area has all muscles removed that attach to the scapula except for those arising from the scapular fossae (lateral surface). Key: 21, triceps brachii caput lateralis; 24, infraspinatus; 25, teres minor; 26, supraspinatus; 30, brachioradialis; A, extensor musculature of the forearm; H, humerus, greater tuberosity; S, scapula, acromion process.

17. *Acromiodeltoideus*.

Joining the scapula to the humerus, this small but stout triangular muscle overlies the point of the shoulder.

ORIGIN. From the full width of the most distal margin of the acromion process muscle fibers arise on the undersurface and tendinous fibers on the outer surface to form a short muscle which then passes over the lateral aspect of the shoulder joint to the upper humerus.

INSERTION. With tendinous fibers developing on the undersurface but fleshy fibers persisting on the outer surface, the muscle inserts into the distal area of the deltoid ridge after first receiving the tendinous and the fleshy fibers

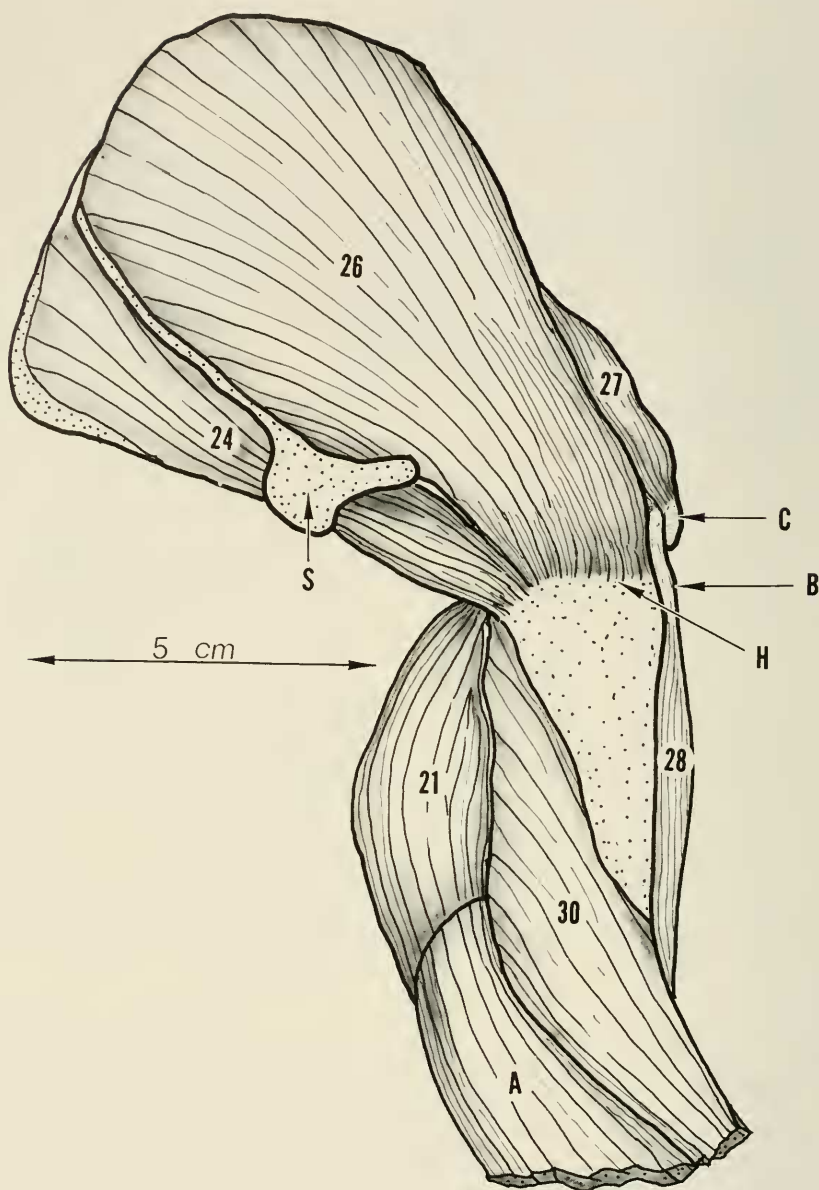


FIGURE 29. Anterolateral view of the right scapula and shoulder to show the detail of insertion of the supraspinatus (26) in relation to the bicipital groove and infraspinatus (24) and subscapularis (27) muscles. Key: 21, triceps brachii caput longus; 24, infraspinatus; 26, supraspinatus; 27, subscapularis; 28, biceps brachii; 30, brachioradialis; A, extensor musculature of the forearm; B, biceps brachii tendon in bicipital groove of humerus; C, humerus, lesser tuberosity; H, humerus, greater tuberosity; S, scapula, acromion process.

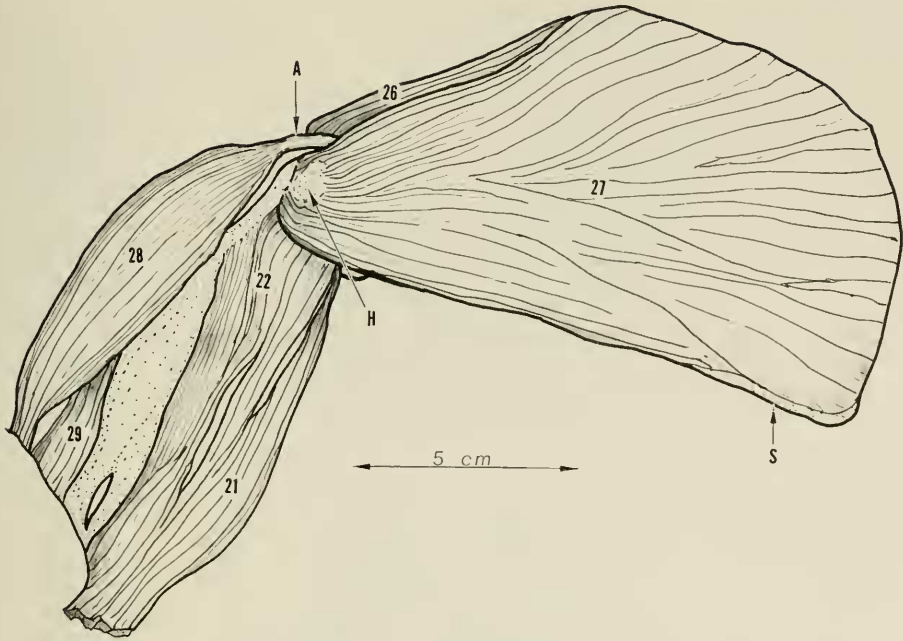


FIGURE 30. Medial view of the right scapula and shoulder to show the detail of subscapularis muscle (27). The biceps brachii (28) has been displaced somewhat anteriorly and the upper tendon lifted out of the bicipital groove of the humerus. Key: 21, triceps brachii caput lateralis; 22, triceps brachii caput medialis; 26, supraspinatus; 27, subscapularis; 28, biceps brachii; 29, brachialis; A, biceps brachii tendon out of bicipital groove; H, humerus, lesser tuberosity; S, scapula, axillary border.

of the spinodeltoideus muscle. The insertion is linear between the insertion of the pectoralis muscles and the origin of the brachioradialis.

ACTION. This muscle can abduct the humerus and possibly give slight external rotation as well.

18. Spinodeltoideus.

This small triangular muscle joins the spine area of the scapula to the humerus via the acromiotrapezius and courses with convergence toward the acromiodeltoideus muscle.

INSERTION. Both fleshy and tendinous fibers join the undersurface of the acromiodeltoideus and proceed to a common insertion with this muscle on the humerus just proximal to the insertion of the clavobrachialis.

ACTION. Acting with the acromiodeltoideus some degree of abduction, extension, and external rotation of the humerus is accomplished.

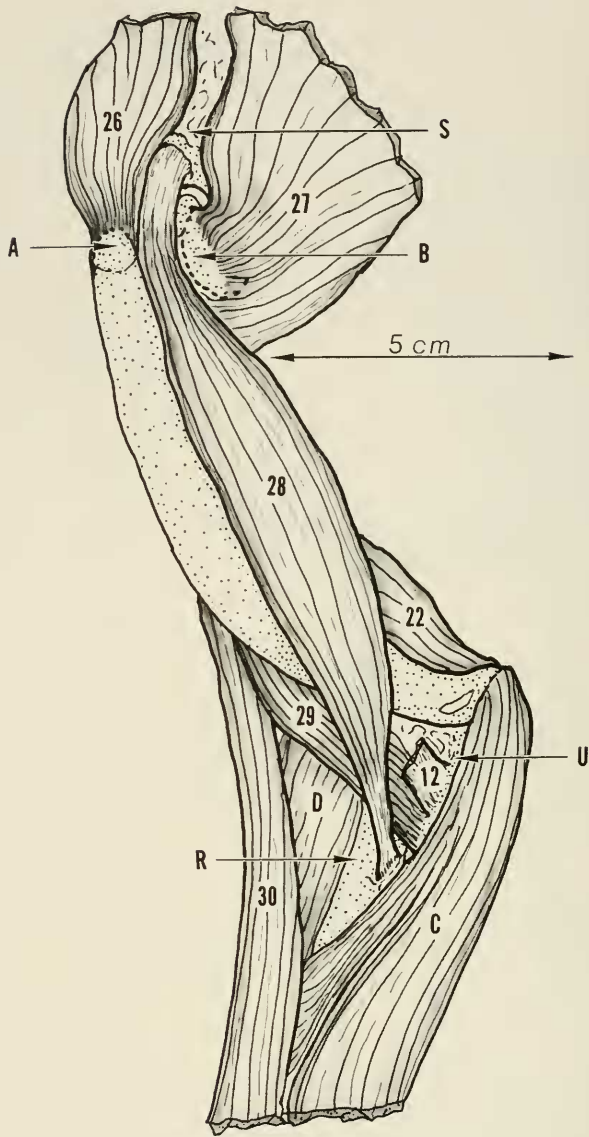


FIGURE 31. Anteromedial view of the right forelimb to show origin and insertion of the biceps brachii muscle (28). The supraspinatus muscle (26) and the subscapularis muscle (27) have been retracted sufficiently to disclose the upper border of the glenoid. The pectoantibrachialis (12) has been excised near its insertion. Key: 12, pectoantibrachialis; 22, triceps brachii caput medialis; 26, supraspinatus; 27, subscapularis; 28, biceps brachii; 29, brachialis; 30, brachioradialis; A, greater tuberosity of the humerus; B, lesser tuberosity of the humerus; C, forearm flexor musculature; D, forearm extensor musculature; S, scapula, supraglenoid area; R, radius; U, ulna.

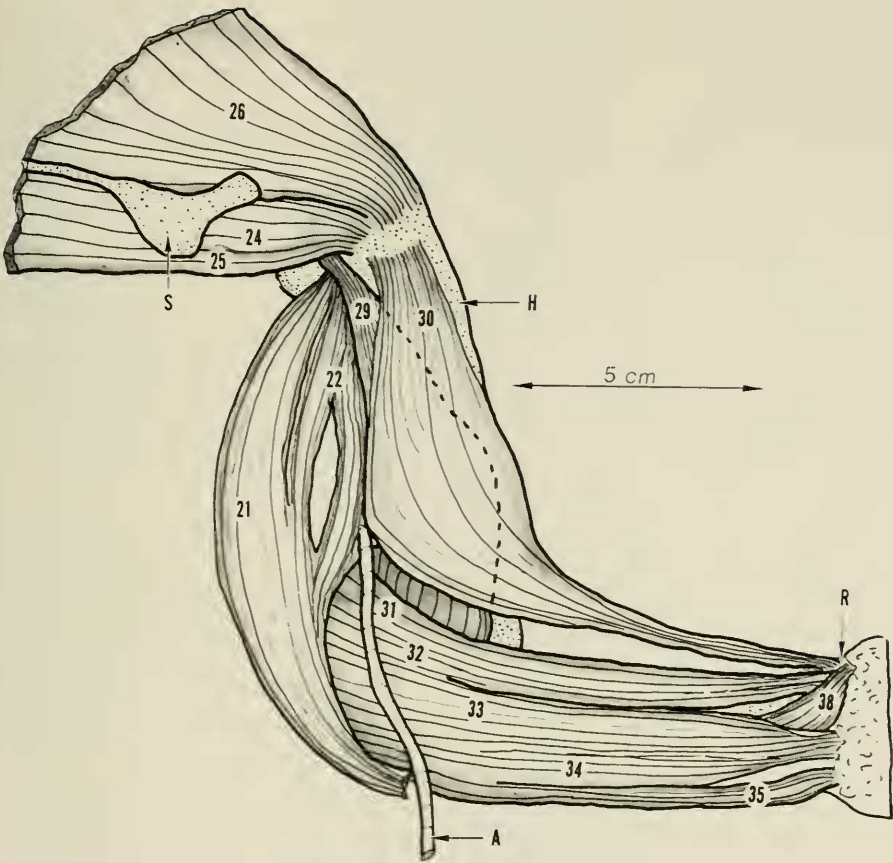


FIGURE 32. Lateral view of the right upper extremity to show the brachialis and the brachioradialis muscles. The triceps mechanism has been displaced posteriorly somewhat and the more superficial muscles of the upper arm and shoulder area have been removed. The superficial sensory branch of the radial nerve is shown displaced from its normal position between the brachioradialis (30) and the radial wrist extensors (31) (32). Key: 21, triceps brachii caput lateralis; 22, triceps brachii caput medialis; 24, infraspinatus; 25, teres minor; 26, supraspinatus; 29, brachialis; 30, brachioradialis; 31, extensor carpi radialis longus; 32, extensor carpi radialis brevis; 33, extensor digitorum communis; 34, extensor digitorum lateralis; 35, extensor digitorum ulnaris; A, radial nerve; H, humerus; R, radius (radial styloid); S, scapula, acromion process.

19. Dorsoepitrochlearis.

This strong, somewhat flat and triangular, fleshy muscle connects the scapula to the forearm on the extensor surface, thus becoming a functional part of the triceps muscle complex.

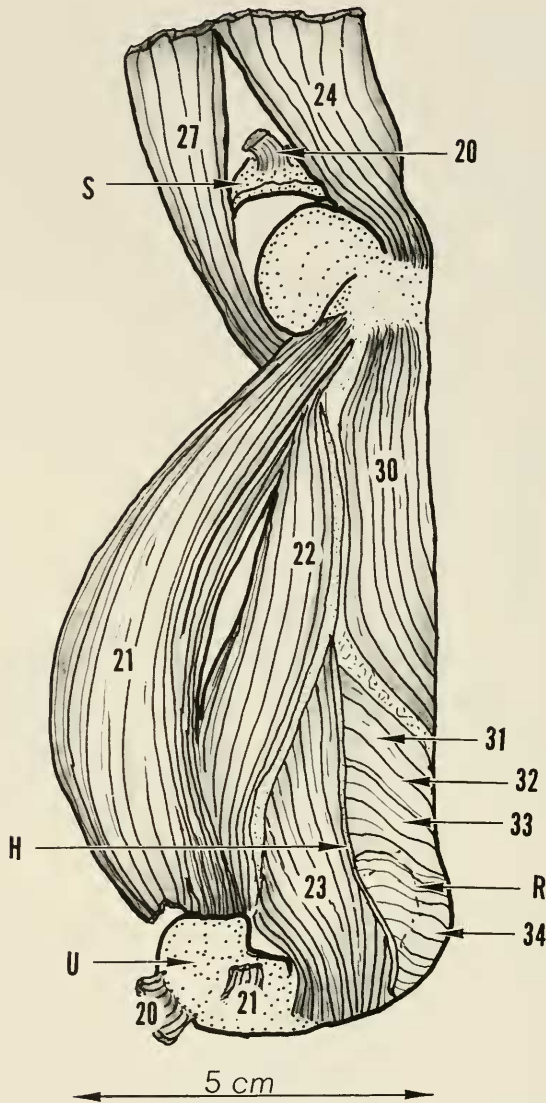


FIGURE 33. Posterior view of the right upper arm to show origin and insertion of anconeus externus (23). Triceps brachii caput lateralis (21) has been detached near its insertion and displaced medialward. The triceps brachii caput longus (20) has been removed except for its tendon of origin and insertion. The scapula is located presenting the axillary border. Key: 20, triceps brachii caput longus; 21, triceps brachii caput lateralis; 22, triceps brachii caput medialis; 23, anconeus externus; 24, infraspinatus; 27, subscapularis; 30, brachioradialis; 31, extensor carpi radialis longus; 32, extensor carpi radialis brevis; 33, extensor digitorum communis; 34, extensor digitorum lateralis; H, humerus, lateral epicondylar crest; R, radius, radial head outline; U, ulna, olecranon process.

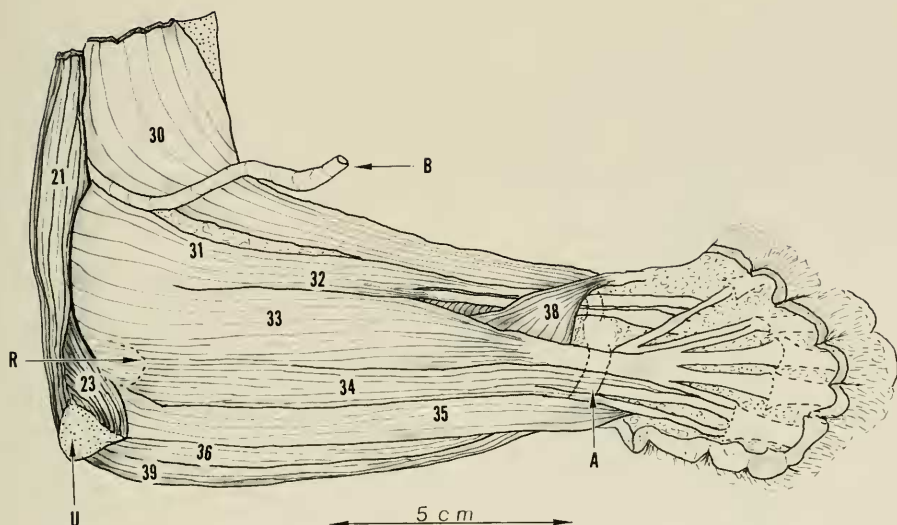


FIGURE 34. Lateral view of right forearm and elbow area to show relationship of the superficial dorsal musculature. Note the transverse dorsal carpal ligament at wrist level (A). Key: 21, triceps brachii caput lateralis; 23, anconeus externus; 30, brachioradialis; 31, extensor carpi radialis longus; 32, extensor carpi radialis brevis; 33, extensor digitorum communis; 34, extensor digitorum lateralis; 35, extensor carpi ulnaris; 36, extensor pollicis et indicis longus; 38, abductor pollicis; 39, flexor carpi ulnaris; A, transverse dorsal carpal ligament; B, radial nerve, distal portion displaced from its bed; R, radius, outline of radial head; U, ulna, olecranon process.

ORIGIN. The muscle arises by fleshy and tendinous fibers from the dorsal three-fifths of the inferior border of the scapula adjacent to and overlying the origin of the teres major muscle. From its origin, the muscle triangulates toward the point of the elbow paralleling the long head of the triceps brachii and overlying the latissimus dorsi.

INSERTION. At the elbow a flat tendon forms which overrides the olecranon process. Except for a few short tendinous fibers which join the tendon of the long head of the triceps brachii, this muscle inserts into the deep fascia of the upper part of the forearm, mostly on the medial side.

ACTION. Strong extension of the elbow is accomplished.

20. *Triceps brachii caput longus.*

This strong spindle-shaped muscle with a tendon at each end joins the scapula to the ulna, and is part of the triceps muscle complex.

ORIGIN. Arising as a heavy tendon with but few fleshy fibers from the inferior surface of the neck of the scapula adjacent to the glenoid, the muscle courses distally down the posterior surface of the humerus between the dorso-

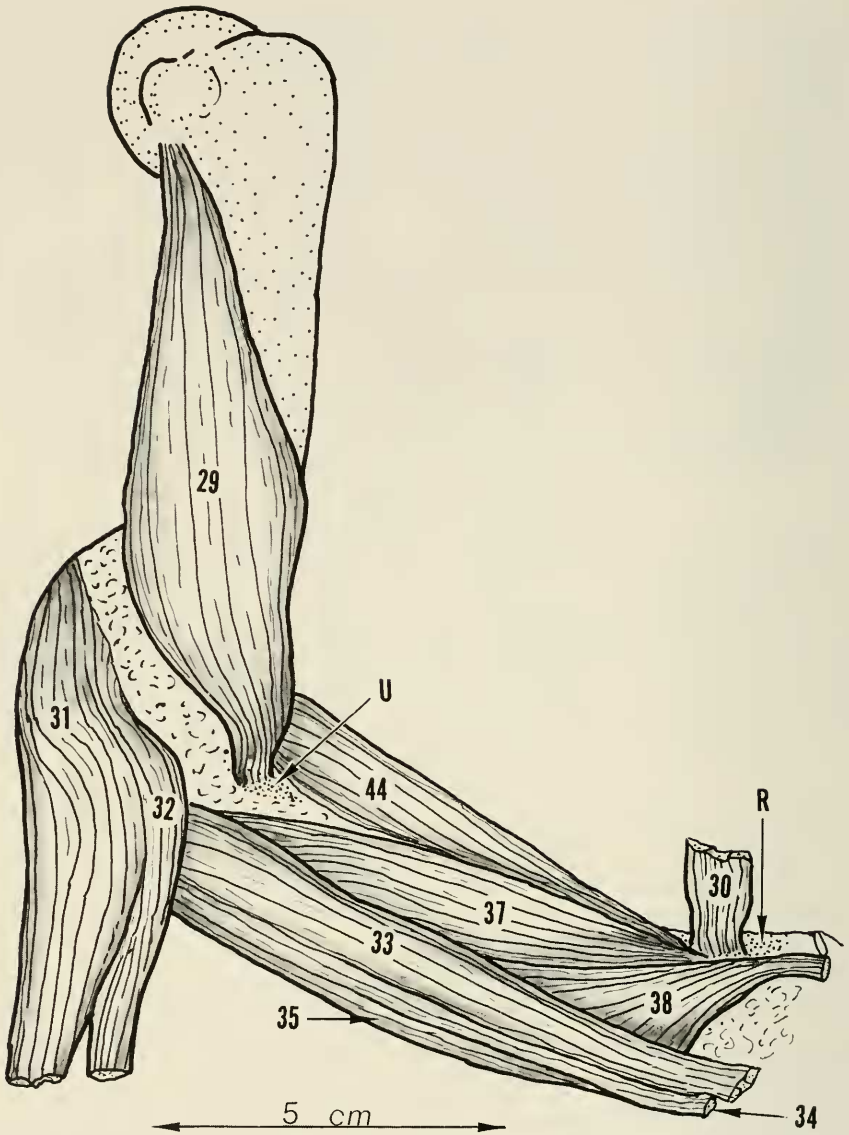


FIGURE 35. An anterolateral view of the right upper extremity to show the relationship of the brachialis (29) to the pronator teres (44) and the supinator (37) muscles. The radial carpal extensors (31) and (32) have been reflected at their origin and the brachioradialis (30) has been excised except for its insertion on the distal radius. The muscles overlying the brachialis (29) have been removed. Key: 29, brachialis; 30, brachioradialis; 31, extensor carpi radialis longus; 32, extensor carpi radialis brevis; 33, extensor digitorum communis; 34, extensor digitorum lateralis; 35, extensor carpi ulnaris; 37, supinator; 38, abductor pollicis longus; 44, pronator teres; R, radius, radial styloid area; U, ulna, coronoid area.

epitrochlearis and the triceps brachii caput lateralis directly to the olecranon process of the ulna.

INSERTION. A heavy tendon terminating this muscle inserts into the olecranon process of the ulna posteriorly and medially. Near its actual bony insertion it receives the tiny tendinous slip from the dorsoepitrochlearis muscle.

ACTION. Strong extension of the elbow results from contraction of this muscle.

21. *Triceps brachii caput lateralis.*

This is another strong fusiform muscle of the triceps muscle complex. This muscle connects the upper humerus with the ulna.

ORIGIN. Fleishy and tendinous fibers arise from the medial surface of the neck of the humerus and adjacent shoulder capsule. The muscle thus formed courses distally to the lateral side of the elbow adjacent to the triceps brachii caput longus and overlies the origin of the brachialis muscle. In its midportion it receives muscle fibers from the medial head of the triceps brachii, and again in its distal portion more fibers from the medial head join in a tendinous raphe.

INSERTION. The muscle terminates at the elbow in a short broad tendon which inserts on the posterolateral side of the olecranon process of the ulna adjacent to and just distal to the insertion of the long head of the triceps brachii.

ACTION. This muscle joins the other members of the triceps muscle complex to produce strong extension of the elbow joint.

22. *Triceps brachii caput medialis.*

This muscle is the lesser of the three triceps muscles and consists of three distinct parts, all of which are closely approximated to the humerus. The long (anconeus posterior) and the intermediate (anconeus internus) portions are more closely associated. The medial division (anconeus medialis) is more apart, much shorter, and much more distal.

ORIGIN. The long portion arises from the posteromedial surface of the upper humerus by thin tendinous fibers from as far proximal as the level of the lesser trochanter. The intermediate portion arises to the lateral side of the long portion but takes origin by fleshy and tendinous fibers more proximally from the posteromedial surface of the neck of the humerus and adjacent capsule of the shoulder joint. Both portions progress distally and unite into a common single muscle belly after the intermediate portion first gives off muscle fibers to the caput lateralis triceps brachii. The medial portion (anconeus medialis) arises distally on the humerus from the posterior surface of the medial epicondylar flare and the fleshy fibers approach the elbow.

INSERTION. The tendons of the caput medialis insert on the medial side of the olecranon process.

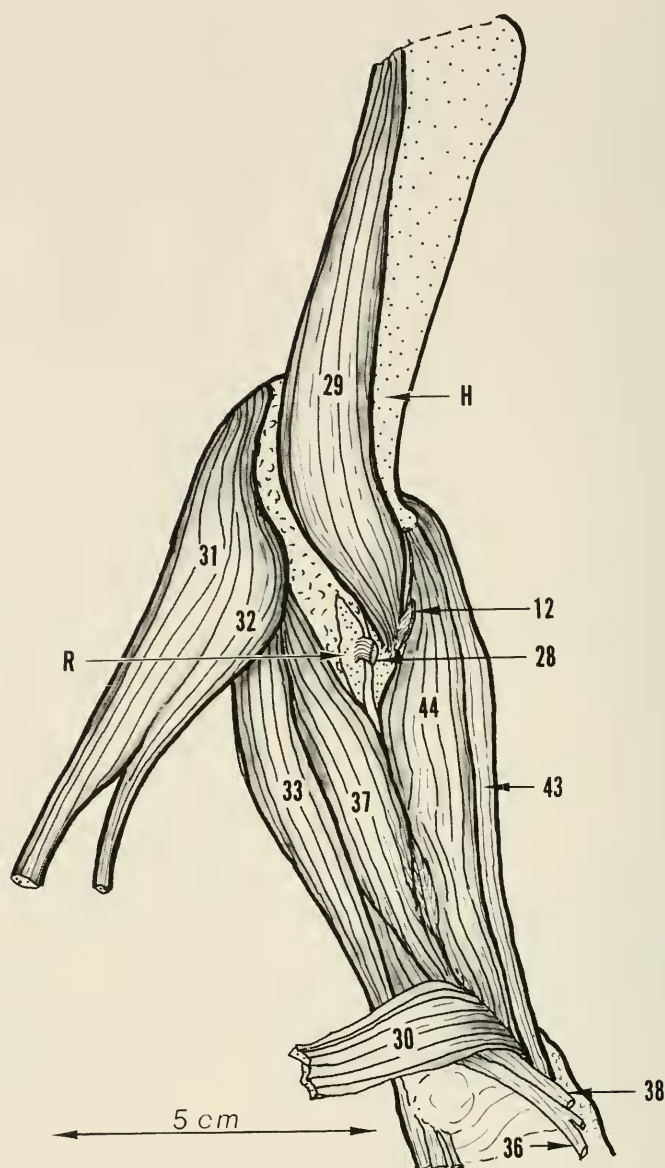


FIGURE 36. Anterior view of the right forearm in midposition to show the pronator (44) supinator (37) relationship. Insertions of the brachialis (29) and the pectoantebrachialis (12) are shown on the coronoid area of the ulna. Also seen is the insertion of the lower biceps tendon on the tubercle of the radius. The radial carpal extensors (31) (32) and the brachioradialis (30) muscles are reflected. Key: 12, pectoantebrachialis; 28, biceps brachii; 29, brachialis; 30, brachioradialis; 31, extensor carpi radialis longus; 32, extensor carpi radialis brevis; 33, extensor digitorum communis; 36, extensor pollicis et indicis longus; 38, abductor pollicis longus; 44, pronator teres; 43, flexor carpi radialis; H, humerus; R, radius, tubercle.

ACTION. This muscle joins with others of the triceps muscle complex to give strong extension of the elbow joint.

23. *Anconeus externus.*

This short fleshy triangular muscle bridging the elbow joint is, in a sense, a counterpart of the anconeus internus (medial part of the caput medialis of the triceps brachii).

ORIGIN. This muscle arises from the posterior surface of the lateral epicondylar flare of the distal humerus by fleshy fibers which then course distally to the lateral side of the olecranon.

INSERTION. Fleshy and tendinous fibers insert laterally on the olecranon along the semilunar notch.

ACTION. This muscle probably assists in extension of the elbow.

24. *Infraspinatus.*

This flat muscle occupying the infraspinatus fossa of the scapula joins the scapula to the humerus.

ORIGIN. Fleshy fibers arising from the infraspinatus fossa of the scapula triangulate toward the upper end of the humerus. The inferior part of the muscle shows a tendency to linear deviation from the remainder of the muscle mass to be designated as the teres minor muscle. At the shoulder the two are joined to form a heavy flat tendon forming part of the tendinous cuff of the shoulder joint.

INSERTION. The tendon fibers insert into the lower posterior area of the greater tuberosity adjacent to and just below the tendon of the supraspinatus.

ACTION. The action is to abduct and externally rotate the humerus.

25. *Teres minor.*

This small muscle lying along the inferior scapular border is hardly distinguishable as separate from the infraspinatus muscle.

ORIGIN. The common origin from the infraspinatus fossa with the infraspinatus muscle and a common tendon with this muscle indicates how close the association actually is.

INSERTION. Tendon fibers join with those of the infraspinatus muscle to insert on the greater tuberosity of the humerus. The most distal fibers are those of the teres minor.

ACTION. The muscle contraction produces external rotation of the humerus with some assistance in abduction as well.

26. *Supraspinatus.*

This large muscle is a strong, flat, fleshy muscle connecting the scapula to the humerus over the top of the shoulder joint.

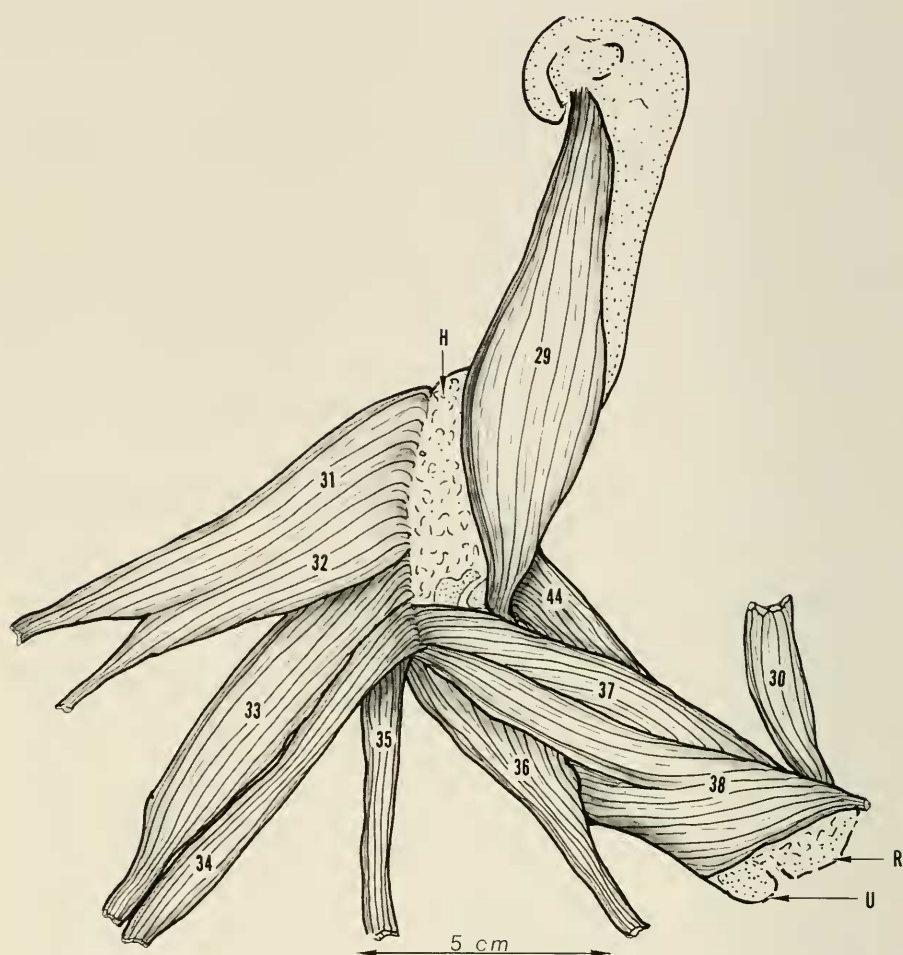


FIGURE 37. Lateral view of the right upper arm with the forearm in midposition to show origin in relationship of forearm extensor musculature. All muscles arising from the lateral epicondylar area have been reflected at their origins except for the supinator (37). Key: 29, brachialis; 30, brachioradialis; 31, extensor carpi radialis longus; 32, extensor carpi radialis brevis; 33, extensor digitorum communis; 34, extensor digitorum lateralis; 35, extensor carpi ulnaris; 36, extensor pollicis et indicis longus; 37, supinator; 38, abductor pollicis longus; 44, pronator teres; H, humerus, connective tissue overlying the bone; R, radius; U, ulna.

ORIGIN. Muscle fibers arise from the entire supraspinatus fossa and converge toward the shoulder joint where a strong flat tendon develops bridging this joint as part of the tendinous cuff.

INSERTION. Tendon fibers enter the greater tuberosity of the humerus ad-

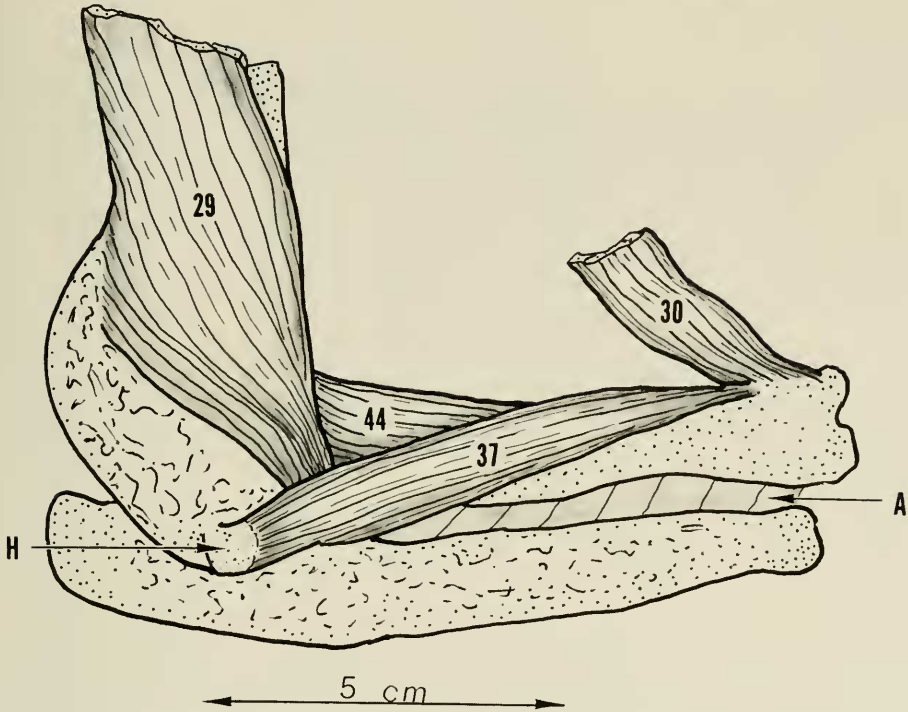


FIGURE 38. Lateral view of the right upper extremity with the forearm in midposition. All forearm extensor musculature has been removed to show origin of supinator muscle (37). The interosseous membrane is shown spanning between the radius and ulna. Key: 29, brachialis; 30, brachioradialis; 37, supinator; 44, pronator teres; A, interosseous membrane; H, humerus, lateral epicondyle.

jacent and superior to the tendon of the infraspinatus and extend to the margin of the bicipital groove.

ACTION. This muscle initiates abduction of the humerus.

27. Subscapularis.

This large triangular muscle lying on the underside of the scapula connects this bone with the humerus.

ORIGIN. Arising as fleshy and tendinous fibers from the entire subscapular surface, the muscle triangulates toward the glenoid where, beyond the scapular spine, it parallels and approximates the supraspinatus muscle. The flat, heavy tendon which then forms bridges the shoulder joint as part of the tendinous cuff of this joint.

INSERTION. The tendon fibers insert into the full width of the lesser tuberosity of the humerus.

ACTION. This muscle is a strong internal rotator of the humerus.

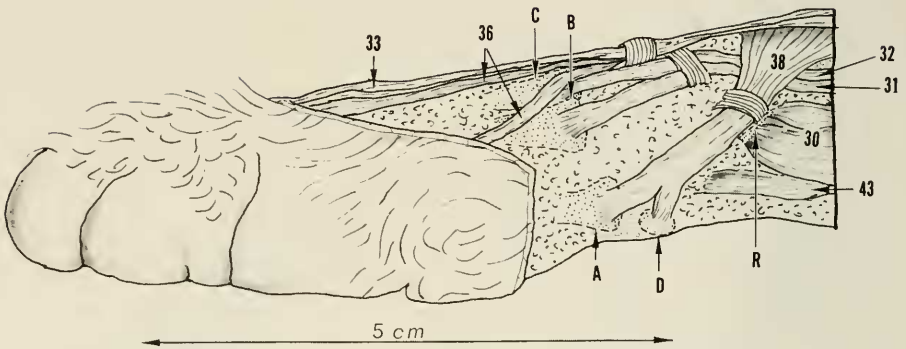


FIGURE 39. An enlarged view of the radial side of the wrist of the right upper extremity. Detail of insertion of the radial carpal extensors (31) and (32) and the abductor pollicis longus (38) is shown. Note dorsal ligamentous structures which hold tendons in position when wrist is dorsiflexed. Key: 30, brachioradialis; 31, extensor carpi radialis longus; 32, extensor carpi radialis brevis; 33, extensor digitorum communis; 36, extensor pollicis et indicis longus; 38, abductor pollicis; 43, flexor carpi radialis; A, metacarpal-1; B, metacarpal-2; C, metacarpal-3; D, radial sesamoid; R, radius, styloid area.

NOTE. The tendons of the subscapularis, supraspinatus, and infraspinatus (with the teres minor) are closely associated with the superior portion of the shoulder joint capsule and form a strong tendinous cuff about the joint. The articular surface of the humerus is thus held snugly against the glenoid surface of the scapula.

28. *Biceps brachii*.

This single-bellied, spindle-shaped muscle with a well developed tendon at each end joins the scapula to the radius.

ORIGIN. From the tubercle on the neck of the scapula at the superior border of the glenoid a heavy tendon arises which passes through the shoulder joint proper to enter the bicipital groove at the upper end of the humerus. From here the tendon expands into a spindle-shaped muscle lying along the anterior surface of the humerus to reach the anterior cubital fossa. The lower tendon now forms and passes across the elbow joint to the proximal radius.

INSERTION. The distal tendon fibers insert into the bicipital tubercle of the radius.

ACTION. This muscle has the combined action of flexion of the elbow and supination of the forearm.

29. *Brachialis*.

This strong thick muscle underlies the brachioradialis muscle in the upper one-half of the humerus, and connects the humerus with the ulna.

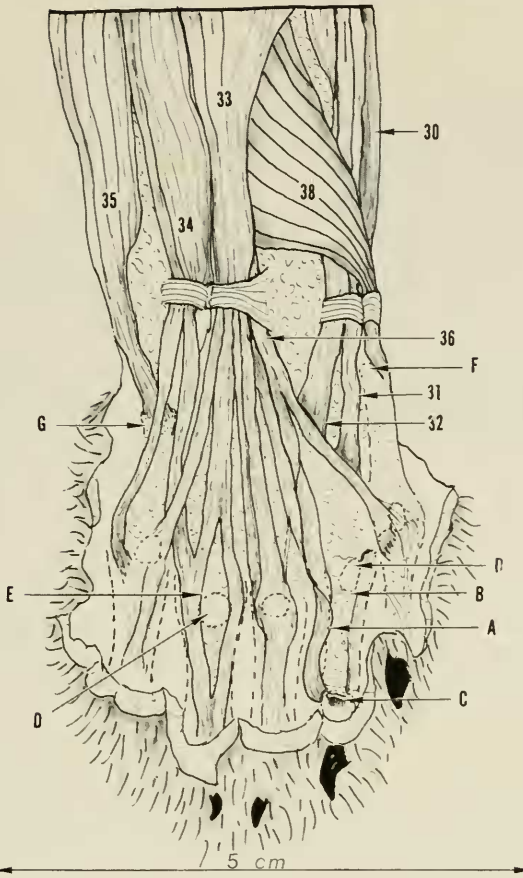


FIGURE 40. An enlarged view of the dorsal and the distal right forearm and hand to show relationship of extensor musculature of the wrist and digits. For digit 2, the extensor aponeurosis overlying the proximal phalanx has been split longitudinally and reflected (A) to show relationship to the sesamoid and proximal joint (metacarpal-phalangeal joint). Also, note ligamentous attachment (B) of sesamoid to base of proximal phalanx, thus causing the sesamoid to move with the proximal phalanx on flexion and extension. Distally, the extensor digitorum communis (33) and the index portion of the extensor pollicis et indicis (36) of the extensor aponeurosis have been divided transversely to show insertion into base of dorsum of the middle phalanx (C). For digit 4, the extensor aponeurosis and common digital extensors have been split longitudinally (E) and spread apart to show relationship to sesamoid. The insertion of the extensor carpi ulnaris (35) into the base of the fifth metacarpal and the abductor pollicis (38) into the base of the first metacarpal are shown. Also note the transverse overlying ligaments at wrist level. Key: 30, brachioradialis; 32, extensor carpi radialis brevis; 33, extensor digitorum communis; 34, extensor digitorum lateralis; 35, extensor carpi ulnaris; 36, extensor pollicis et indicis longus; 38, abductor pollicis; A, split extensor aponeurosis of digit 2; B, ligament attaching sesamoid to proximal phalanx; C, insertion of long extensor tendon on digit 2; D, sesamoid bone; E, split extensor tendon of digit 4; F, base of metacarpal 1; G, base of metacarpal 5.

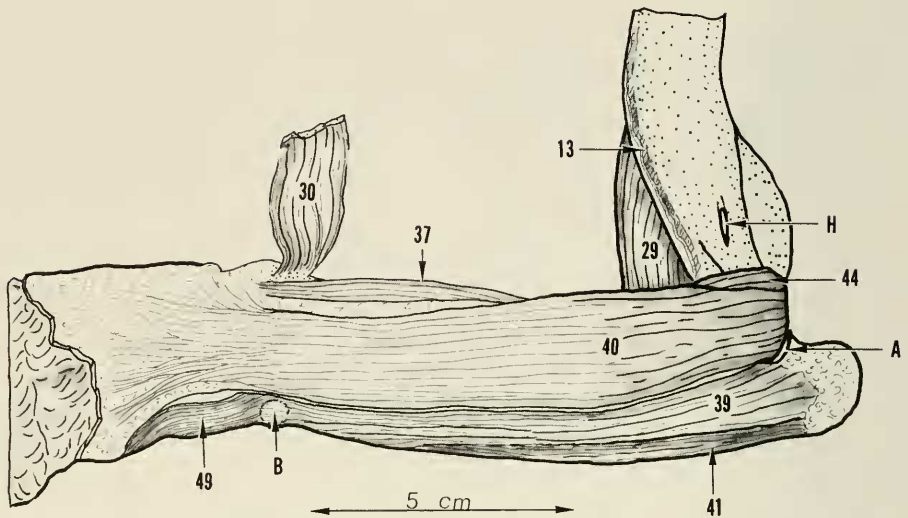


FIGURE 41. Medial view of right upper extremity with forearm in midposition, thus presenting its volar or flexor surface. This figure shows the origin and relationship of the superficial forearm flexor musculature. The abductor digiti quinti has been displaced outward from the shaft of the fifth metacarpal. Key: 13, pectoralis major, insertion; 29, brachialis; 30, brachioradialis; 37, supinator; 40, palmaris longus; 41, flexor digitorum profundus (ulnar head); 44, pronator teres; 49, abductor digiti quinti; A, elbow joint; B, pisiform bone; H, humerus, medial epicondylar foramen.

ORIGIN. Muscle fibers arise from almost the entire posteromedial surface of the humerus, from the neck of the humerus above to the lateral epicondylar ridge below. Entering the area of the cubital fossa a tendon is formed which bridges the elbow joint.

INSERTION. The tendon of the brachialis muscle inserts on the medial side of the proximal ulna adjacent to the insertion of the pectoantebrachialis tendon.

ACTION. This muscle is a strong flexor of the elbow joint.

30. *Brachioradialis.*

This is a long elbow-spanning fleshy muscle connecting the proximal humerus with the distal radius.

ORIGIN. Arising as thin flat tendinous fibers from the surface of the upper part of the brachialis muscle and from along the deltoid ridge of the humerus from the greater tuberosity to the humeral crest, a fleshy muscle belly promptly develops which spans the elbow joint anterolaterally then tapers gradually following the radial border of the forearm to the area of the radial styloid.

INSERTION. Tendon fibers developing on the underside of the muscle distally insert into the bone of the radial styloid.

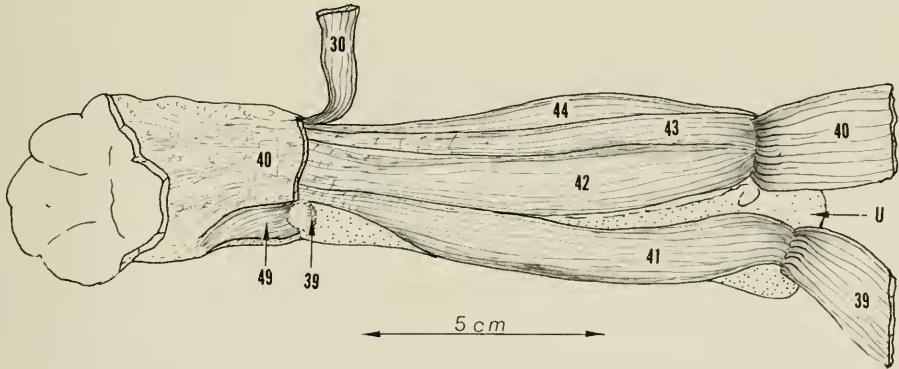


FIGURE 42. Volar view of right forearm in its distal portion and volar medial view of proximal portion as the forearm is in a slightly pronated position. The palmaris longus (40) and the flexor carpi ulnaris (39) have been divided and reflected to show origins and relationships of the deeper flexor musculature. The musculature of the flexor digitorum profundus can, by origin, be divided into three distinct portions, the more superficial humeral head (42) and the ulnar head (41), and the deeper central head (45). Not visible in this view, the central head has an ulnar, radial, and interosseus portion which will be shown later. Distally, all of the profundi group are joined together at the wrist as a broad tendinous structure from which separate the five profundi tendons, one passing to each digit. At wrist level the tendon passes under the deep carpal ligament. Also distally, and in addition to the main flexor tendon, the profundi give rise to the sublimi and lumbrical musculature which will be described later. Key: 30, brachioradialis; 39, flexor carpi ulnaris; 40, palmaris longus; 41, flexor digitorum profundus, ulnar head; 42, flexor digitorum profundus, humeral head; 43, flexor carpi radialis; 44, pronator teres; 49, abductor digiti quinti; U, ulna, olecranon area.

ACTION. This strong muscle has the double action of flexing the elbow and supinating the forearm.

31. Extensor carpi radialis longus.

This muscle is the more radial of the two radial carpal extensors.

ORIGIN. This muscle arises in common with the extensor carpi radialis brevis by muscular fibers from the proximal three-fourths of the lateral epicondylar ridge. The common muscle extends about half-way down the forearm before dividing into the longus and brevis portions. In the midforearm the longus portion lies between the brachioradialis muscle and the extensor digitorum communis muscle. At wrist level, the tendon passes through a groove on the dorsal surface of the radius adjacent to the styloid process. The overlying transverse dorsal carpal ligament forms a compartment for the tendon.

INSERTION. Bridging the wrist joint the tendon inserts at the base of metacarpal 2 into a tubercle on the dorsum and slightly to the radial side.

ACTION. This muscle is a strong dorsiflexor and radial flexor of the wrist joint.

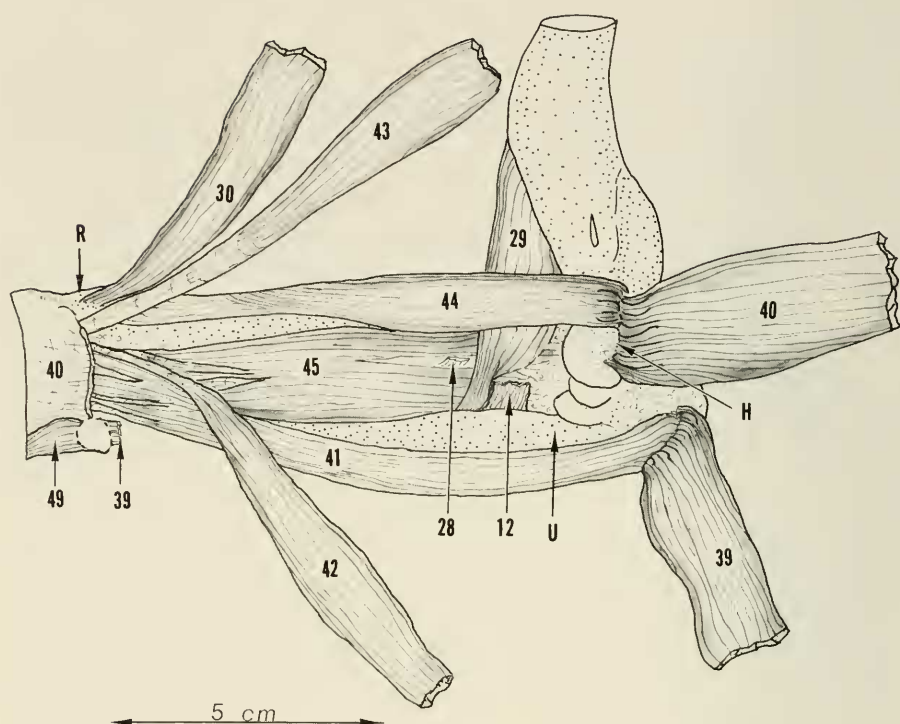


FIGURE 43. Volar view of right forearm with most of the flexor musculature reflected to show the deeply situated flexor digitorum profundus (central head) (45), with its fibers joining the ulna humeral divisions at near-wrist level. Also shown in this view are the insertions of the biceps tendon (28), the pectoantibrachialis tendon (12), and the brachialis muscle (29). The origin of the pronator teres (44) in relation to the palmaris longus (40) is visualized. Key: 12, pectoantibrachialis; 28, biceps brachii; 29, brachialis; 30, brachioradialis; 39, flexor carpi ulnaris; 40, palmaris longus; 41, flexor digitorum profundus (ulnar head); 42, flexor digitorum profundus (humeral head); 43, flexor carpi radialis; 44, pronator teres; 45, flexor digitorum profundus (central head); H, humerus, medial epicondyle; R, radius, styloid process; U, ulna.

32. Extensor carpi radialis brevis.

This muscle is a partner of the extensor carpi radialis longus and also connects the humerus to the hand.

ORIGIN. In common with the extensor carpi radialis longus from the lateral epicondylar ridge, this muscle represents the lower fibers of origin. The tendon forming in midforearm parallels that of the longus and passes with this tendon in the groove at the distal end of the radius.

INSERTION. Spanning the wrist joint the tendon inserts into the dorsum at the base of metacarpal 3.

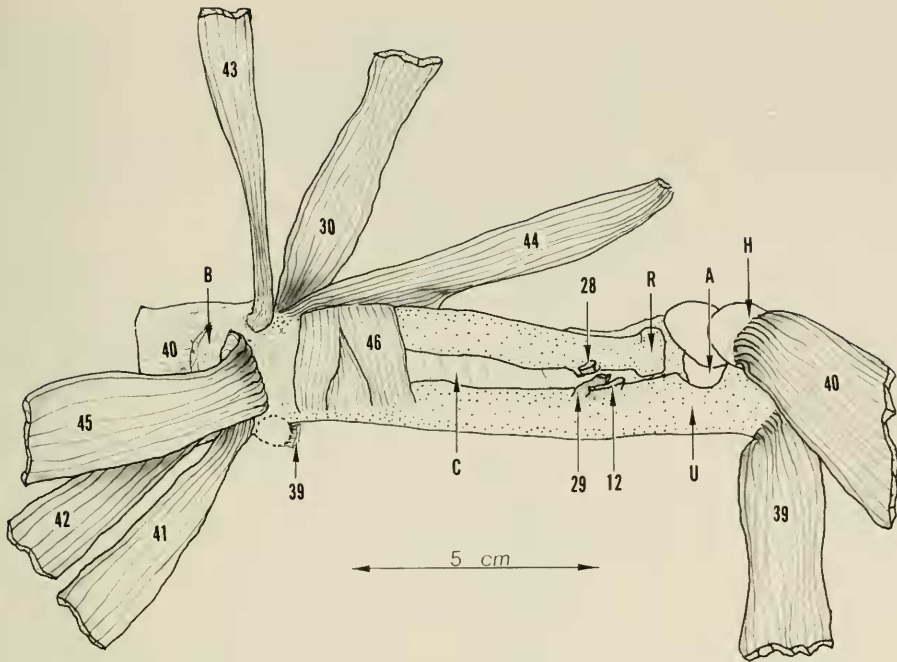


FIGURE 44. Volar view of right forearm. All flexor musculature has been reflected to expose the radius and ulna with intervening interosseus membrane. The flexor digitorum profundus musculature has been reflected distally where the tendons are entering the carpal canal beneath the deep carpal ligament. Distally, the pronator quadratus muscle (46) is shown spanning the two forearm bones. Note insertions of the biceps brachii (28), brachialis (29), and pectoantebrachialis (12). Key: 12, pectoantebrachialis; 28, biceps brachii; 29, brachialis; 30, brachioradialis; 39, flexor carpi ulnaris; 40, palmaris longus; 41, flexor digitorum profundus (ulnar head); 42, flexor digitorum profundus (humeral head); 43, flexor carpi radialis; 44, pronator teres; 45, flexor digitorum profundus (central head); 46, pronator quadratus; A, elbow joint; B, deep carpal ligaments; C, interosseus membrane; H, humerus, medial epicondyle; R, radius, head; U, ulna.

ACTION. Owing to its more central location and insertion, the brevis serves only to dorsiflex the wrist.

33. *Extensor digitorum communis*.

This muscle, along with the extensor digitorum lateralis, represents the long extensors of the digits except for the thumb. The musculature is in the forearm and the tendons extend distally to the middle phalanges.

ORIGIN. The muscle arises in common with the extensor digitorum lateralis from the lateral epicondylar ridge of the humerus down to and including the lateral epicondyle. The extensor digitorum lateralis fibers are the more distal

in origin. At its origin, the muscle overlies the extensor carpi radialis brevis and appears to share some fibers with this muscle. On the dorsum of the forearm the muscle lies between the radial-carpal extensors and the extensor digitorum lateralis. At wrist level four separate tendons develop and pass through a groove at the distal radius, following which they spread out and span to each of the digits 2, 3, 4, and 5. Over the metacarpal area small tendinous slips may develop which rejoin the same or adjacent tendon at the metacarpal-phalangeal joint area.

INSERTION. At the metacarpal-phalangeal joint level each tendon expands and joins into the extensor hood and the extensor aponeurosis mechanism, but the central fibers continue down the dorsum of the proximal phalanx to insert at the base of the middle phalanx. At the metacarpal-phalangeal joint level a light fibrous attachment is noted to the sesamoid at this site. The sesamoid, however, is more associated with the joint capsule than with the extensor tendon.

ACTION. The primary action of the tendon is to extend the metacarpal-phalangeal joint through the hood mechanism. However, with the metacarpal-phalangeal joint stabilized so that hyperextension does not occur, the central fibers then act to extend the proximal interphalangeal joint.

34. *Extensor digitorum lateralis.*

This partner of the extensor digitorum communis muscle provides an extra long extensor tendon for the fourth and fifth digits.

ORIGIN. The muscle arises in common with the extensor digitorum communis representing the more distal portion of this origin, the lateral humeral epicondyle and epicondylar ridge. Separation from the communis occurs on the ulnar side of this muscle and near the wrist two individual tendons develop which pass through a separate compartment in a groove of the distal radius. From here, the more radial of the two tendons passes beneath the communis tendon of digit 5 to the midmetacarpal area to join with the communis tendon of digit 4 at the extensor hood level. The more ulnar tendon parallels the common extensor tendon of digit 5 to join into the extensor hood of this digit on the ulnar side.

INSERTION. Joining with the communis extensor tendon the insertion is the same; namely, the base of the middle phalanx of digits 4 and 5.

ACTION. The action is the same as that of the communis tendon for the fourth and fifth digits.

35. *Extensor carpi ulnaris.*

This strong muscle joins the humerus with the hand and serves to balance the action of the radial carpal extensors.

ORIGIN. This muscle arises from the lateral epicondyle just radial to the

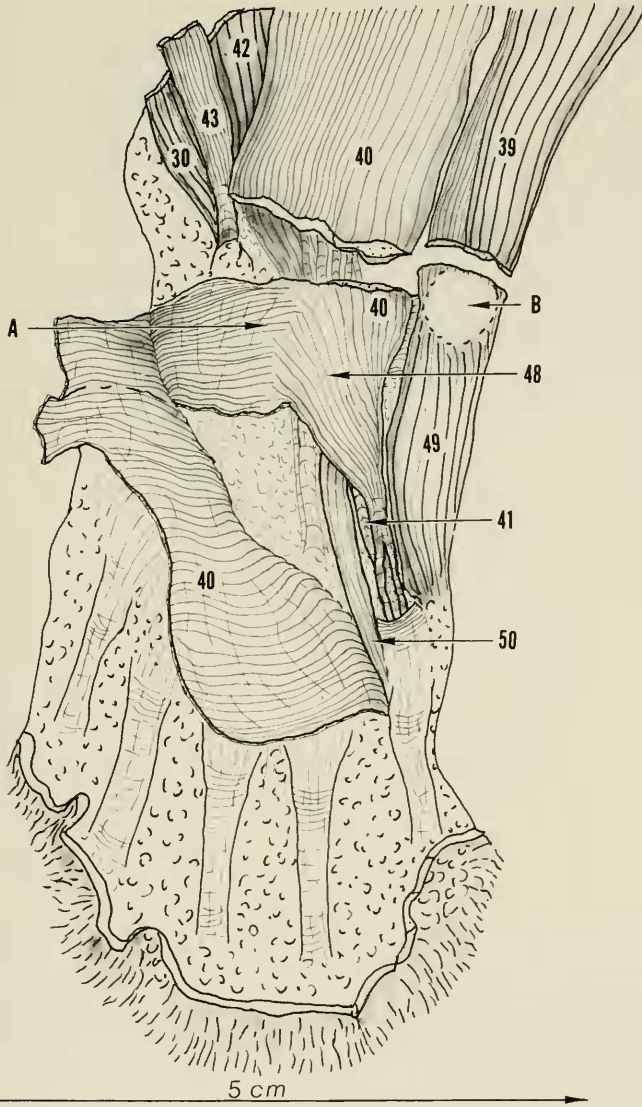


FIGURE 45. An enlarged view of the volar surface of the right forepaw. The volar pad has been removed and the palmaris longus tendon (40) divided. Distally, the palmaris longus fascial expansion (palmar fascia) has been reflected radialward to disclose the origin of the sublimis muscle (48) for digit 5. Note the continuation of deep muscle fibers from the underside of the palmaris longus joining with muscle fibers arising from the deep transverse carpal ligament to form the sublimis muscle of this fifth digit. Key: 30, brachioradialis; 39, flexor carpi ulnaris; 40, palmaris longus; 41, flexor digitorum profundus, tendons from the ulnar head; 42, flexor digitorum profundus (humeral head); 43, flexor carpi radialis; 48, flexor digitorum sublimis for digit 5; 49, abductor digiti quinti; 50, opponens digiti quinti; A, transverse carpal ligament; B, pisiform bone.

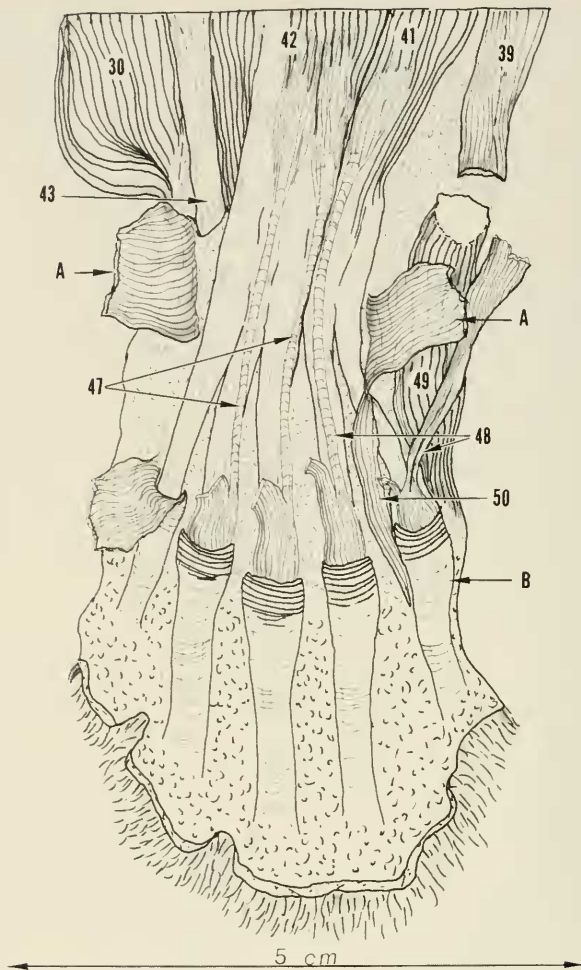


FIGURE 46. Enlarged view of volar surface of the right hand. The palmar fascia has been completely removed except for the groups of distal fibers which reinforce the sublimi tendons. The flexor tendon sheath has been resected a bit distally for digits 2, 3, 4, and 5 to show the broadening of the sublimis to completely cover the profundus tendon at this site. Note again, there is no sublimis tendon for digit 1. The palmaris longus fibers for this digit attach to the rim of the flexor tendon sheath. The transverse carpal ligament (A) has been divided and reflected to show the origin of the sublimis of digits 2, 3, and 4. The sublimis of digit 5 has been reflected from its origin and displaced ulnward. Also shown are the profundus flexor tendons of all digits and how these tendons arise from the proximal musculature. Key: 30, brachioradialis; 39, flexor carpi ulnaris; 41, flexor digitorum profundus (ulnar head); 42, flexor digitorum profundus (humeral head); 43, flexor carpi radialis; 47, flexor digitorum sublimis (radial); 48, flexor digitorum sublimis (ulnar); 49, abductor digiti quinti; 50, opponens digiti quinti; A, transverse carpal ligament; B, fibrous flexor tendon sheath.

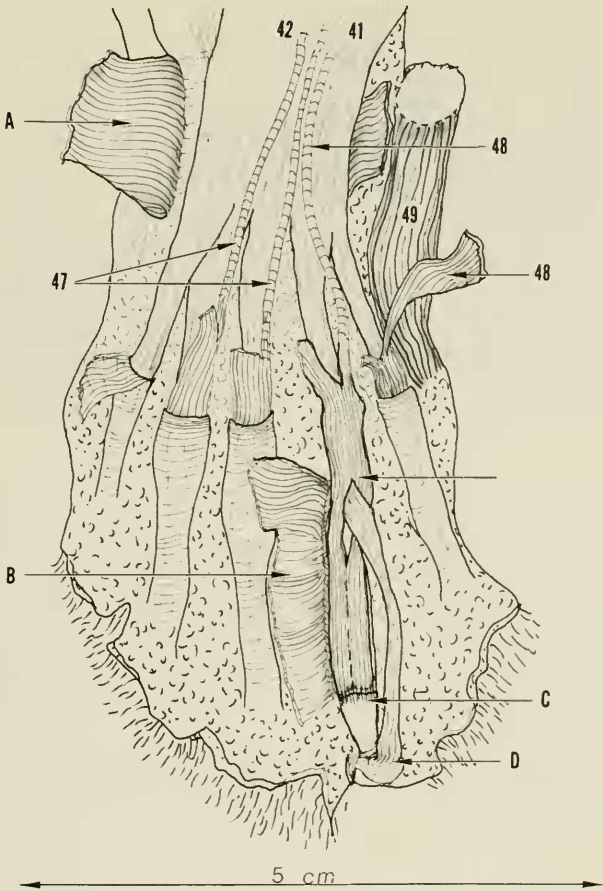


FIGURE 47. Enlarged view of the volar aspect of the right hand. On digit 4 the fibrous flexor tendon sheath (A) has been divided along the ulnar margin and reflected radialward to show the contents of the flexor tunnel. The concentration of transverse fibers on the flexor tendon sheath provides the pulley mechanism of the sheath, thus preventing bow-stringing of the flexor tendons when activated. Note the division and rejoining of the sublimis tendon to allow the profundus to come through. The sublimis then continues distally to insert in the base of the middle phalanx (B). The profundus flexor tendon continues in this sheath to the distal interphalangeal-joint level, inserting at the base of the terminal phalanx which is in a hyperextended position at rest. The deep transverse carpal ligament (D) has been divided and reflected. This broad ligament has its radial attachment mainly to the radial sesamoid and volar wrist joint capsule along the radial side of the navicular-lunate bone. On the ulnar side, attachment is mainly along the base of the pisiform with attachment also to the wrist joint capsule in the area of the triquetrum. Key: 41, flexor digitorum profundus (ulnar head); 42, flexor digitorum profundus (humeral head); 47, flexor digiti sublimis (radial); 48, flexor digiti sublimis (ulnar of the fifth digit); 49, abductor digiti quinti; A, transverse carpal ligament; B, fibrous tendon sheath of digit 4, reflected; C, insertion of sublimis flexor tendon; D, insertion of profundus flexor tendon.

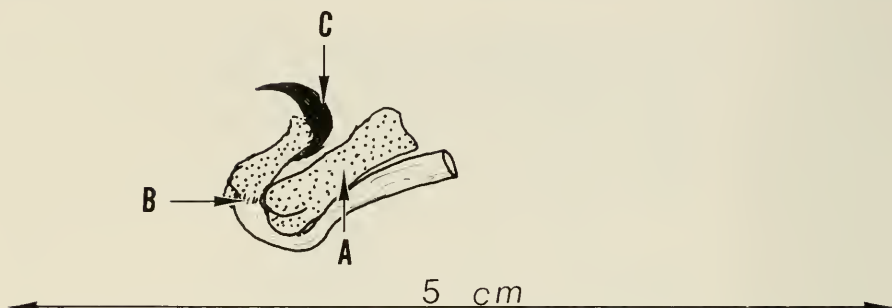


FIGURE 48. Enlarged ulnar view of the middle and distal phalanges of digit 4 to show the hyperextended position of the terminal phalanx and the insertion of the profundus flexor tendon. Note the close approximation of the claw to the terminal phalanx. Key: A, middle phalanx; B, insertion of profundus flexor tendon on distal phalanx; C, claw.

origin of the supinator muscle adjacent and distal to the extensor digitorum lateralis muscle. The muscle passes along the ulnar border of the dorsum of the forearm adjacent to the extensor digitorum lateralis. Near the wrist a strong tendon is formed which broadens and passes over the distal ulna with an interposed bursa between the tendon and the bone.

INSERTION. Spanning the carpal area, the tendon continues distally to the ulnar side of the base of the fifth metacarpal where it inserts into a slight bony protuberance at this site.

ACTION. The direct action of this muscle is to ulnaflex the wrist but, if this motion is opposed, the action becomes one of dorsiflexion of the wrist joint.

36. *Extensor pollicis et indicis.*

This muscle provides long extensor action for the thumb and an assistance to the communis extensor tendon of digit 2.

ORIGIN. The muscle arises entirely from the proximal two-thirds of the ulna, beginning at the articular notch level and extending distally along the ulnar crest. The origin is just posterior to that of the abductor pollicis longus muscle. The muscle underlies the extensor digitorum communis muscle and the tendon which forms passes through the same compartment at the distal radius as the communis tendons. Just distal to the wrist, the tendon divides into two separate tendons which continue radiusward. The more radial one goes directly to the base of the thumb, the other underlies the communis tendon to reach the ulnar side of digit 2.

INSERTION. The pollicis tendon inserts into the base of the proximal phalanx of digit 1 after spreading out somewhat in a hoodlike manner at the metacarpal-phalangeal joint level. The indicis tendon, which is approximately twice the size of the communis tendon of this digit, joins into the extensor hood on the

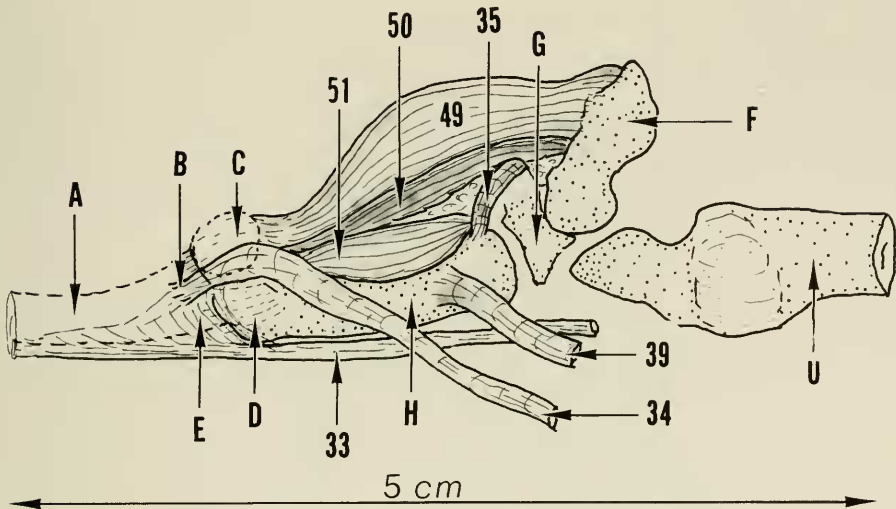


FIGURE 49. Enlarged ulnalateral view of ulna border of the right hand to show relationship of muscles of tendons about the fifth metacarpal (H). Note insertion of the extensor digiti lateralis (34) is mainly into the base of the proximal phalanx, the communis extensor, forming the main extensor aponeurosis. Although in close proximity the base of the fifth metacarpal does not articulate with the joint surface on the triquetrum but rather more radial on the hamate. The pisiform bone has been reflected outward a bit for a cleared view of the ulna carpal extensor and flexor tendons. Key: 33, extensor digitorum communis; 34, extensor digitorum lateralis; 35, extensor carpi ulnaris; 39, flexor carpi ulnaris; 49, abductor digiti quinti; 50, opponens digiti quinti; 51, flexor digiti quinti brevis; A, proximal phalanx; B, insertion of extensor digitorum lateralis; C, sesamoid bone; D, collateral ligament at the metacarpal phalangeal joint; E, extensor hood at the metacarpal phalangeal joint; F, pisiform; G, triquetrum; H, metacarpal (fifth); U, ulna, distal end.

ulnar side of the communis tendon, then joins with the communis tendon for the remainder of its course.

ACTION. The pollicis portion extends the metacarpal-phalangeal joint of the thumb and acts as an adductor of the thumb as well. The indicis portion has the identical action to that of the comunis tendon of digit 2.

37. Supinator.

This deep, somewhat flat forearm muscle joins the humerus to the radius.

ORIGIN. Heavy tendinous fibers arise from the small area on the distal and most prominent part of the lateral humeral epicondyle just ulnaward of the origin of the extensor carpi ulnaris muscle. From its origin the muscle passes directly toward the radius and promptly begins its insertion.

INSERTION. Insertion is into the proximal three-fourths of the radius start-

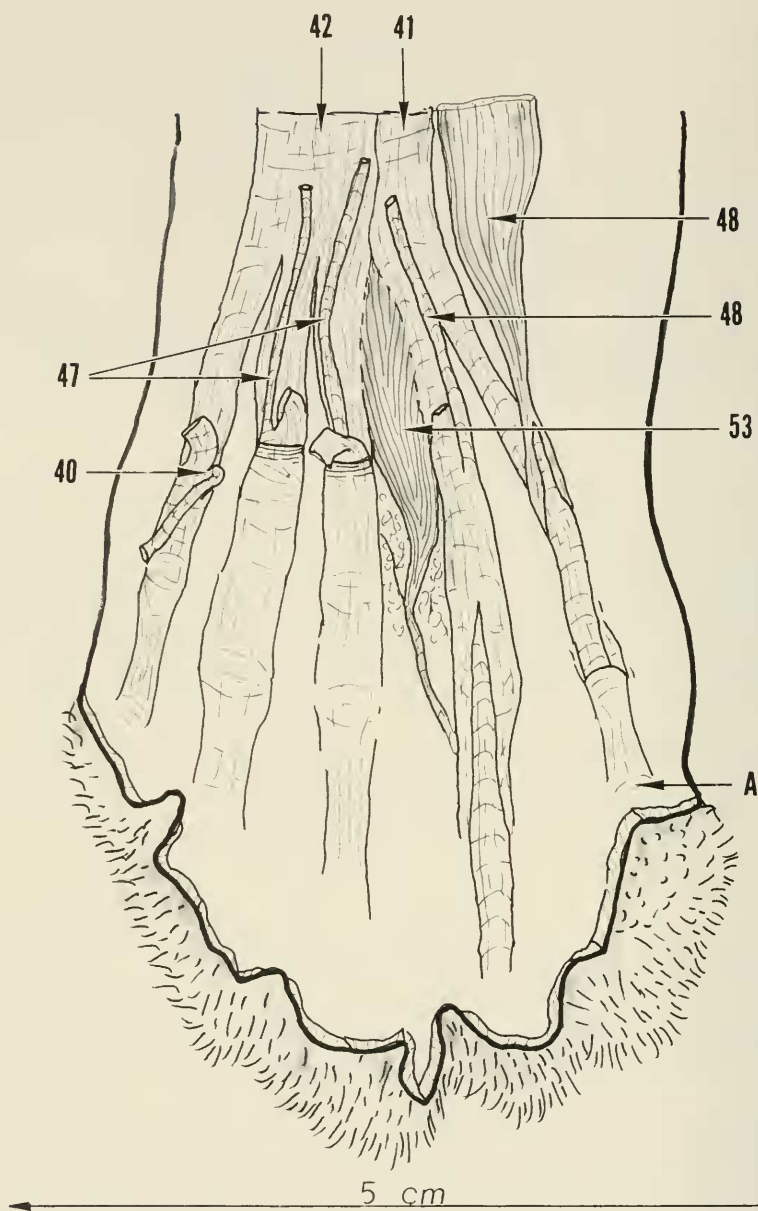


FIGURE 50. Palmar view of the right hand to show specifically the origin and insertion of the single lumbrical muscle in this specimen (53). In this plate, the entire flexor sheath has been removed from digit 4 and the proximal one-half removed from digit 5. For digit 1, the palmar fascia attached to the rim of the flexor sheath has been split and reflected (40). Key: 40, palmaris longus; 41, flexor digiti profundus (ulnar head); 42, flexor digiti profundus (humeral head); 47, flexor digitorum sublimis (radial); 48, flexor digitorum sublimis (ulnar); A, digit 5.

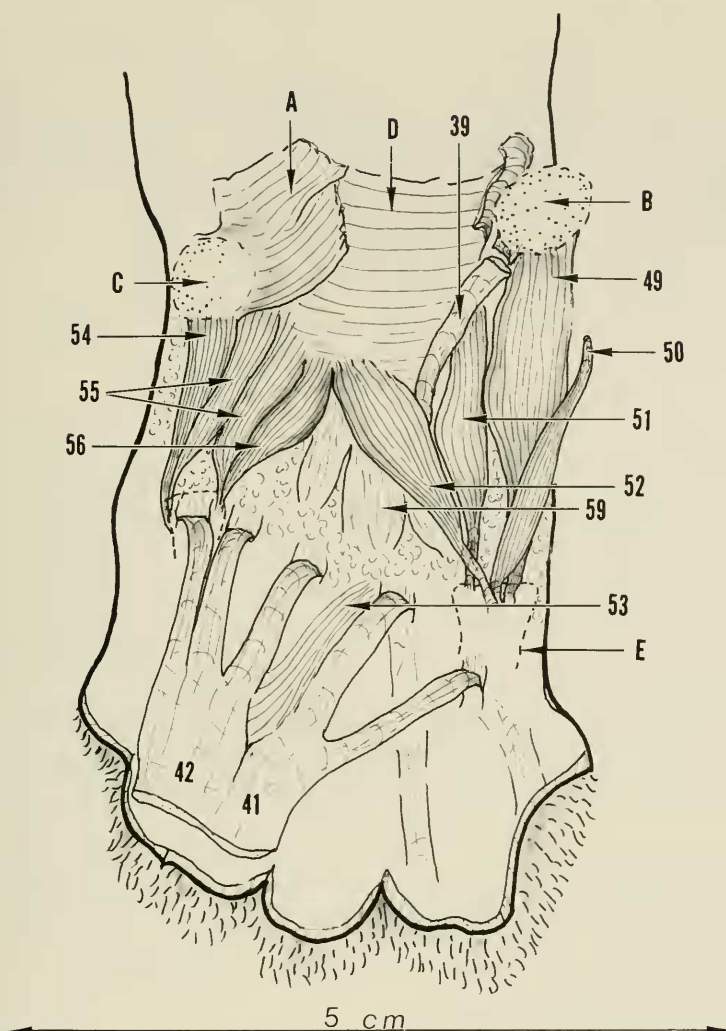


FIGURE 51. Enlarged palmar view of right hand. The long digital flexor tendons have been reflected distally to show the intrinsic hand muscles grouped about the first and fifth metacarpals. These muscles are termed respectively the thenar and hypothenar muscle groups. The opponens digiti quinti (50) has been detached from its origin and reflected ulnaward. Note absence of an opponens pollicis muscle. The flexor pollicis brevis of digit 1 (55) has two heads designated as radial and ulnar by their position. A heavy fibrous capsule at the wrist joint forms the floor of the carpal tunnel. Key: 39, flexor carpi ulnaris; 41, flexor digitorum profundus (ulnar head); 42, flexor digitorum profundus (humeral head); 49, abductor digiti quinti; 50, opponens digiti quinti; 51, flexor digiti quinti brevis; 52, adductor digiti quinti; 53, lumbricali; 54, abductor pollicis brevis; 55, flexor pollicis brevis; 56, adductor pollicis; 59, interossei; A, transverse carpal ligament—reflected; B, pisiform bone; C, radial sesamoid bone; D, volar capsule of wrist joint; E, proximal phalanx of fifth digit.

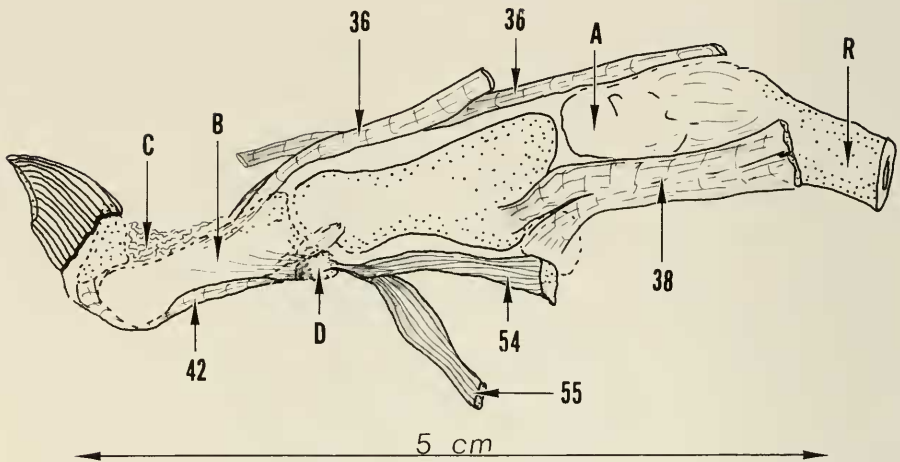


FIGURE 52. An enlarged radial view of the right first digit to show the relationship of the extensor, extrinsic, and intrinsic muscles. Both pollicis and indicis portions of the extensor pollicis et indicis tendons are shown. The indicis part lies behind the pollicis tendon. Note the more distant extension of the radial fibers of the pollicis tendon at the insertion at the base of the proximal phalanx. Note also the location of elastic tissue (dorsal elastic ligament) which keeps the distal phalanx hyperextended. On voluntary flexion of the distal phalanx, the elastic tissue simply stretches. There is no extensor tendon as such inserting on the distal phalanx at digit 1 nor on the distal phalanges of the remaining digits. Visible in this view is the radial head of the flexor pollicis brevis (55). Key: 36, extensor pollicis et indicis; 38, abductor pollicis longus; 42, flexor digitorum profundus (humeral head); 54, abductor pollicis brevis; 55, flexor pollicis brevis (radial head); A, carpus (multangular); B, proximal phalanx; C, elastic tissue (dorsal elastic ligament); D, sesamoid; R, radius, distal end.

ing on the posterior and lateral aspects at the bicipital tubercle level and terminating in tendinous fibers at the point of maximum bow of the radius. Thus strong mechanical advantage is provided for its action.

ACTION. This muscle is a strong supinator of the forearm.

38. *Abductor pollicis longus.*

This deep extensor muscle joins the ulna to the thumb.

ORIGIN. This muscle arises from the lateral aspect of the ulna all the way from the articular notch to the end of the bone. The origin is adjacent to and on the radial side of the extensor pollicis et indicis origin. Some fleshy fibers of origin also arise from the proximal interosseus membrane and adjacent opposing surface of the radius. The muscle fibers converge in a triangular configuration to emerge from under the extensor digitorum communis in the distal forearm, where they then pass over the radial carpal extensors toward the radial styloid. The tendon now formed passes in the groove of the radius at the radial styloid level.

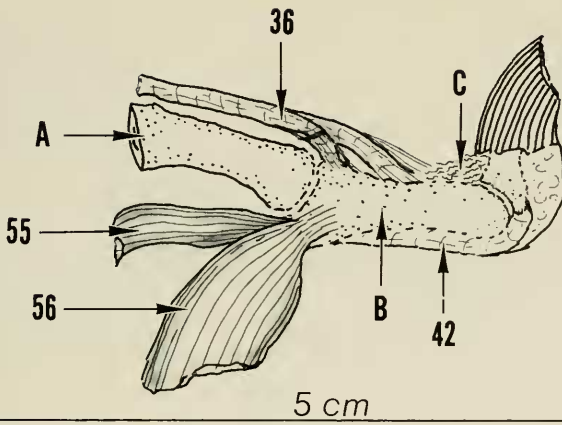


FIGURE 53. Enlarged view of the ulnar side of the right first digit to show the extrinsic and intrinsic muscles on this side. The principal insertion of the extensor pollicis (36) is into bone somewhat to the ulnar side of the midline space of the proximal phalanx. The radial fibers, as noted in figure 52, insert somewhat more distally. Visible in this view is the ulnar head of the flexor pollicis brevis (55). Key: 36, extensor pollicis et indicis (pollicis part); 42, flexor digitorum profundus (humeral head); 55, flexor pollicis brevis (ulnar head); 56, adductor pollicis; A, metacarpal of digit 1; B, proximal phalanx of digit 1; C, elastic tissue (dorsal elastic ligament).

INSERTION. Emerging from the distal compartment of the radius the tendon splits into a lesser one-fourth which inserts volarly into the radial sesamoid, and a greater three-fourths which inserts into a bony tubercle to the radial side of the dorsum of the base of the first metacarpal.

ACTION. By virtue of its insertion this muscle acts to abduct the thumb metacarpal, and also to radiflex the wrist to some degree. Like other extensor musculature it can assist in supination of the forearm.

39. *Flexor carpi ulnaris.*

This large strong muscle occupies the ulnar side of the volar surface of the forearm and lies adjacent to the palmaris longus muscle. It extends from the elbow area to the hand.

ORIGIN. Arising by muscular tendinous fibers from the medial surface of the lower part of the olecranon crest the origin just overlies the origin of the ulnar head of the flexor profundus digitorum muscles with a few fibers seemingly in common. Other but lesser fleshy fibers arise from the adjacent medial aspect of the olecranon and over the joint capsule in this area, and a few from the humerus along the articular ridge of the medial condyle. The muscle is elongated, fusiform in type, and in its course down the forearm it overlies all but the proximal part of the flexor digitorum profundus (ulnar head). The

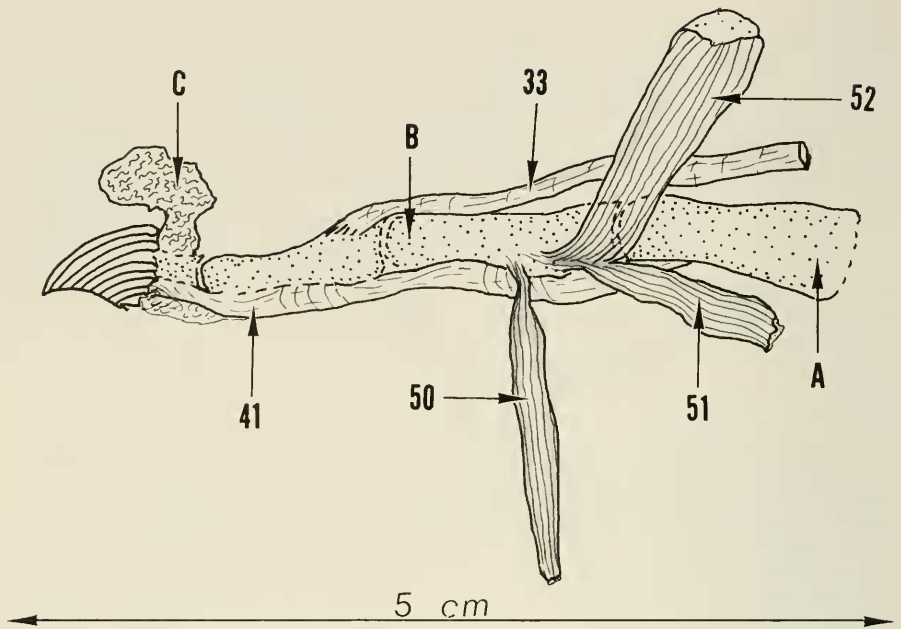


FIGURE 54. An enlarged radiolateral view of digit 5 to show insertion of extensor digitorum communis (33) at the base of the middle phalanx. The elastic tissue at distal joint level has been reflected from its attachment to the middle phalanx, thus allowing the distal joint to assume a more flexed position. Insertions of the intrinsic musculature on the radial side of digit 5 are shown. Key: 33, extensor digitorum communis; 41, flexor digitorum profundus (ulnar head); 50, opponens digiti quinti; 51, flexor digiti quinti brevis; 52, adductor digiti quinti; A, metacarpal of digit 5; B, proximal phalanx; C, elastic tissue (dorsal elastic ligament).

tendon of insertion begins to appear about halfway down the muscle. The muscle fibers continue as far distally as the pisiform bone.

INSERTION. At the carpal level the tendon inserts into and encompasses the pisiform bone but continues to pass deeply into the palm to its final insertion at the volar surface of the base of the fifth metacarpal bone.

ACTION. This muscle is a strong volar flexor of the wrist and gives ulnar flexion of the wrist as well.

40. *Palmaris longus*.

This is the most prominent muscle on the volar surface of the forearm. It is a large, broad, flat muscle which lies superficially adjacent to the flexor carpi ulnaris and connects the humerus with the hand. A tendinous surface presents on the distal two-thirds of the muscle.

ORIGIN. Arising as the outermost muscle from the distal three-fourths of

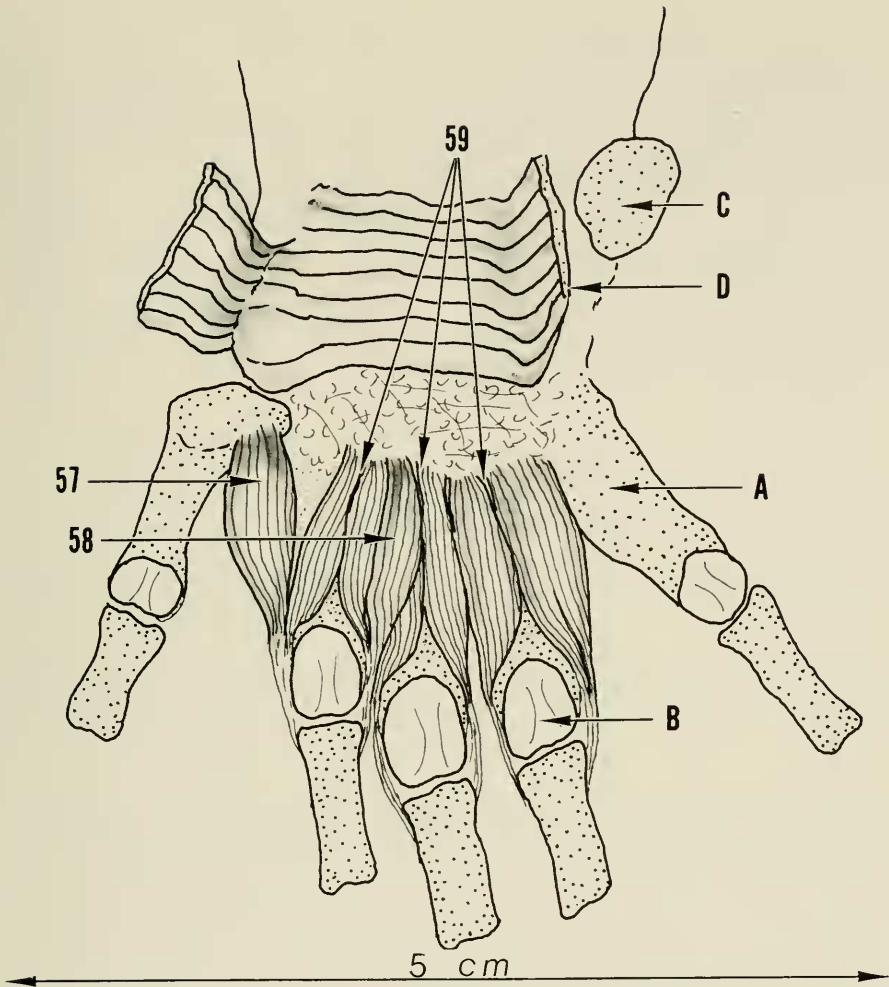


FIGURE 55. An enlarged palmar (volar) view of the right hand with all muscles and tendons removed except for the abductor (57) and adductor (58) digiti secundus and the three interossei (59). The interossei constitute the deepest layer of muscles, as the abductor and adductor digiti secundi lie a bit superficial to them. Key: 57, abductor digiti secundi; 58, adductor digiti secundi; 59, interossei; A, metacarpal, digit 5; B, head of fourth metacarpal; C, pisiform bone; D, transverse carpal ligament—cut and reflected.

the medial epicondyle, the origin overlies the distal one-half of the origin of the pronator teres muscle. Tendinous fibers appear the width of the muscle at the junction of the proximal and middle thirds, and continue distally as a broad tendinous sheath to the wrist. The superficial fibers spread out over the palm forming a dense palmar fascia. Connective tissue fibers from this fascia extend

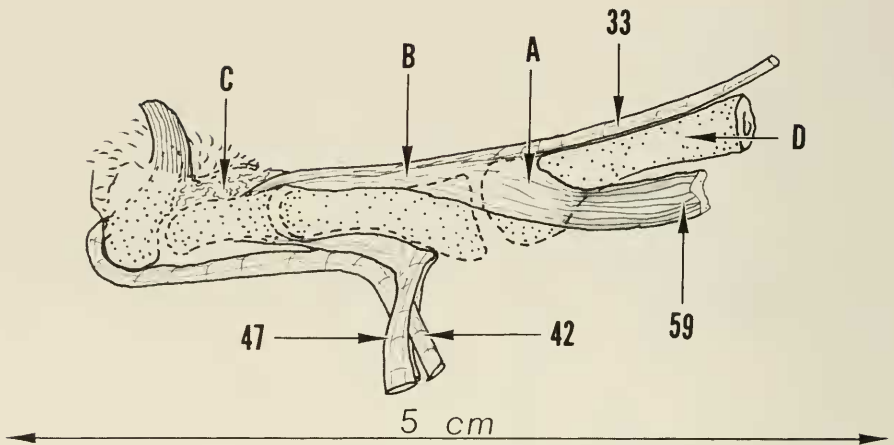


FIGURE 56. A radiolateral view of digit 4 of the right hand to show the pattern of insertion of all interossei muscles except the one to the radial side of digit 2. Note how the flat interosseus tendon joins the extensor aponeurosis at the extensor hood level overlying the metacarpal phalangeal joint. The anatomical relationship of the long extensor probably allows the interossei to extend the proximal interphalangeal joint when the metacarpal phalangeal joint is in hyperextension. It appears that the hood mechanism probably checks the excursion of the long extensor thus limiting its action on the proximal interphalangeal joint when in the hyperextended position. Key: 33, extensor digitorum communis; 44, flexor digitorum profundus; 47, flexor digitorum sublimis; 59, interossei; A, extensor hood; B, extensor aponeurosis; C, elastic tissue (dorsal elastic ligament); D, metacarpal of digit 4.

into the pads of the palm and the digits. The dense palmar fascia shows three major fibrous bands extending toward the bases of digits 2, 3, and 4, with lesser concentrations of fibers passing toward the bases of digits 1 and 5. Fibrous extensions of the palmar fascia also pass deeply into the palm forming septum-like structures which attach to the fibrous flexor tendon sheaths on either side of the metacarpal heads. The interval between the metacarpal heads becomes a hiatus through which the volar digital nerves and vessels pass into the digits. When the palmaris longus muscle is divided just above the wrist and the distal portion reflected, the undersurface can be observed. Here it is noted that toward the ulnar side at wrist level muscle fibers continue and separate from the main more superficial tendinous portion. These muscle fibers are now joined by additional muscle fibers arising from the deep transverse carpal ligament. This combined muscle shortly terminates in a small discreet tendon which then promptly splits into two halves which enter the fibrous flexor tendon sheath of digit 5 as a sublimis tendon. At its point of entry, this small tendon is reinforced by main fibers from the palmar fascia. The palmar fascia proper, which spreads over the palm with the concentration of fibers and bands towards the digits 2, 3, and 4, shows these bands attaching to the fibrous flexor sheath and

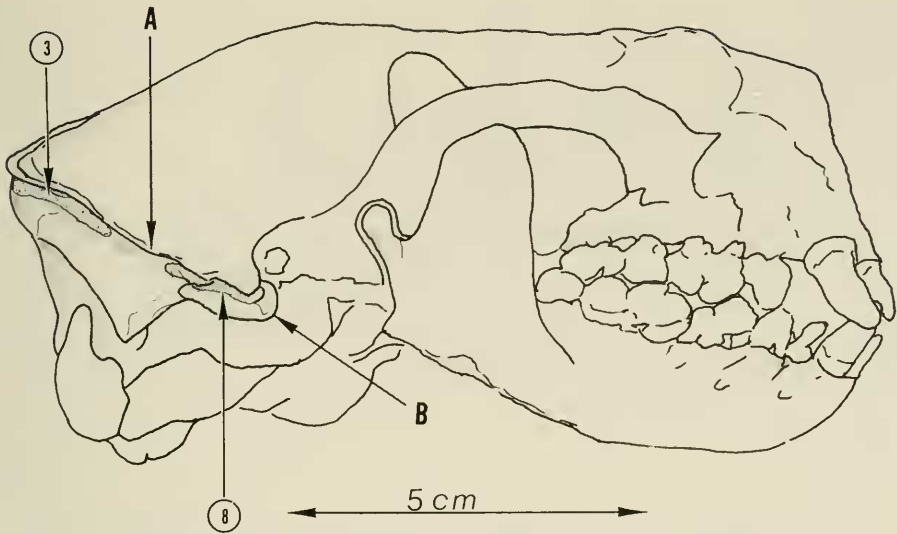


FIGURE 57. Skull, right lateral view. Key: 3, clavotrapezius (origin); 8, rhomboideus capitis (origin); A, lambdoidal crest; B, mastoid process.

entering the sheath to reinforce the respective sublimi tendons to these digits. For the thumb, the lesser fibrous band simply attaches to the fibrous flexor digital sheath as there is no sublimis tendon for this digit.

INSERTION. As noted from the description above, the palmaris longus muscle has three functions; namely, cupping of the palm by tensing the palmar fascia, volar flexion of the wrist, and reinforcing the flexor sublimi tendons which flex the proximal interphalangeal joints of digits 2, 3, 4, and 5.

41. *Flexor digitorum profundus* (ulnar head).

This muscle represents part of the profundus flexor mechanism of the digits. The remaining part is the flexor digitorum profundus, humeral head and central head.

ORIGIN. Musculotendinous fibers arise from the medial olecranon ridge beneath the origin of the flexor carpi ulnaris with additional fleshy fibers of origin continuing distally from the medial surface of the ulna in its upper half tapering along the ulna crest. Tendon fibers begin to appear in the lower half of the muscle but muscle fibers continue as far distally as the wrist. Slightly above wrist level, junction occurs with the humeral and central heads with five resulting strong tendons which pass through the carpal tunnel under the deep transverse carpal ligament and then pass one to each digit. It is to be noted that the contribution from the ulnar head makes up the tendons for digits 4 and 5.

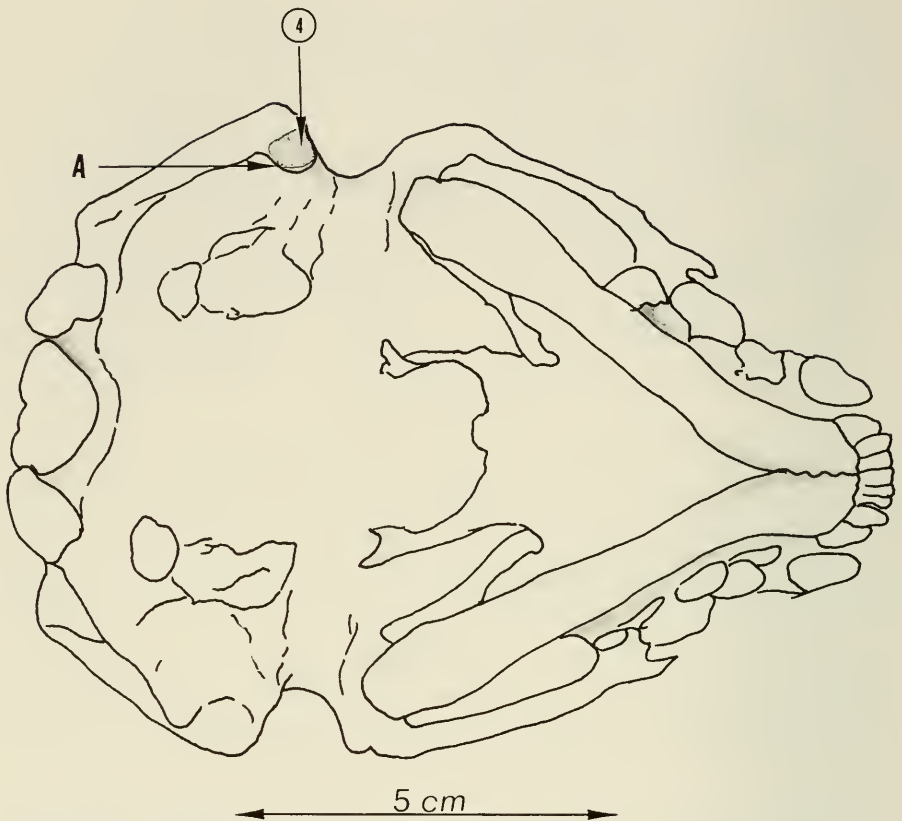


FIGURE 58. Skull, volar view. Key: 4, cleidomastoideus (origin); A, mastoid process.

INSERTION. Flexor profundus tendons of digits 4 and 5 enter the fibrous flexor tendon sheath of the metacarpal-head level passing through a split of the flexor sublimis tendon in the proximal phalanx area, the tendon continues distally in its sheath to its insertion on the volar surface of the base of the terminal or distal phalanx.

ACTION. The profundus tendon flexes the terminal finger joint and all proximal finger joints as well.

42. *Flexor digitorum profundus* (humeral head).

This is a strong centrally placed forearm muscle connecting the humerus with the digits. It is part of the profundus flexor mechanism.

ORIGIN. Tendinous and muscular fibers arise from the medial humeral epicondyle under the distal one-half of the origin of the palmaris longus muscle and just distal to the origin of the flexor carpi radialis muscle. In the forearm,

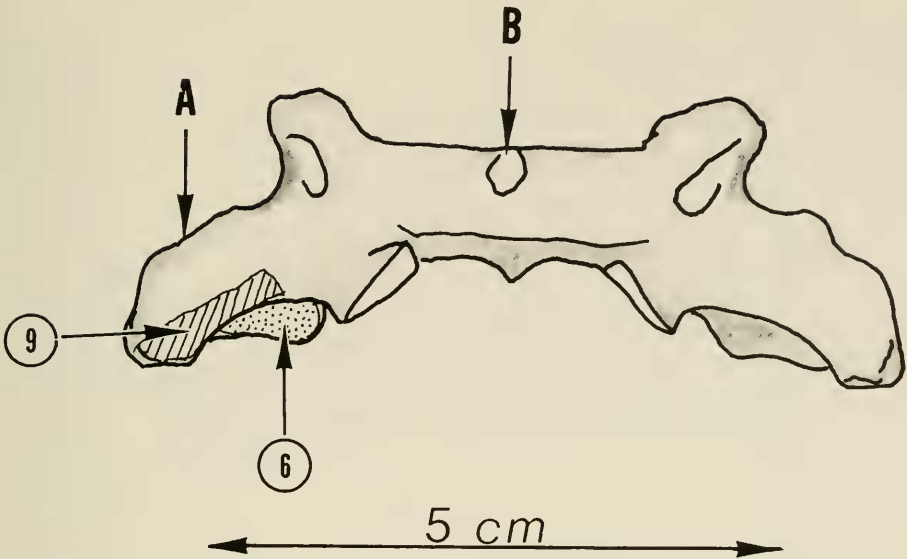


FIGURE 59. Atlas, volar view. Key: 6, omotracheon (origin); 9, rhomboideus profundus (origin); A, transverse process; B, anterior tubercle.

the muscle lies between the flexor digitorum profundus (ulnar head) and the flexor carpi radialis. Insertional tendon begins to develop about halfway to the wrist and, at wrist level, junction with the ulnar and central heads occurs and the five resulting tendons pass through the carpal tunnel and on to the digits. The humeral head contributes to the tendons of digits 1, 2, and 3.

INSERTION. The profundus tendons of digits 2 and 3 insert as described for those of digits 4 and 5. For the thumb, a similar fibrous flexor tendon sheath is present but there is no sublimis tendon and only two phalanges. Insertion is into the base of the terminal phalanx on its volar surface.

ACTION. The profundus tendon flexes the distal joint of the digits and all proximal digital joints as well.

43. Flexor carpi radialis.

This strong muscle with tendinous fibers at each end connects the humerus to the hand.

ORIGIN. The heavy tendinous fibers of origin arise from the medial humeral epicondyle under the proximal one-half of the origin of the palmaris longus muscle and adjacent to the origin of the humeral head of the flexor digitorum profundus muscle. The flexor carpi radialis is fusiform in shape and passes down the volar aspect of the forearm under the palmaris longus muscle and adjacent to the humeral head of the flexor digitorum profundus. At wrist level, a heavy

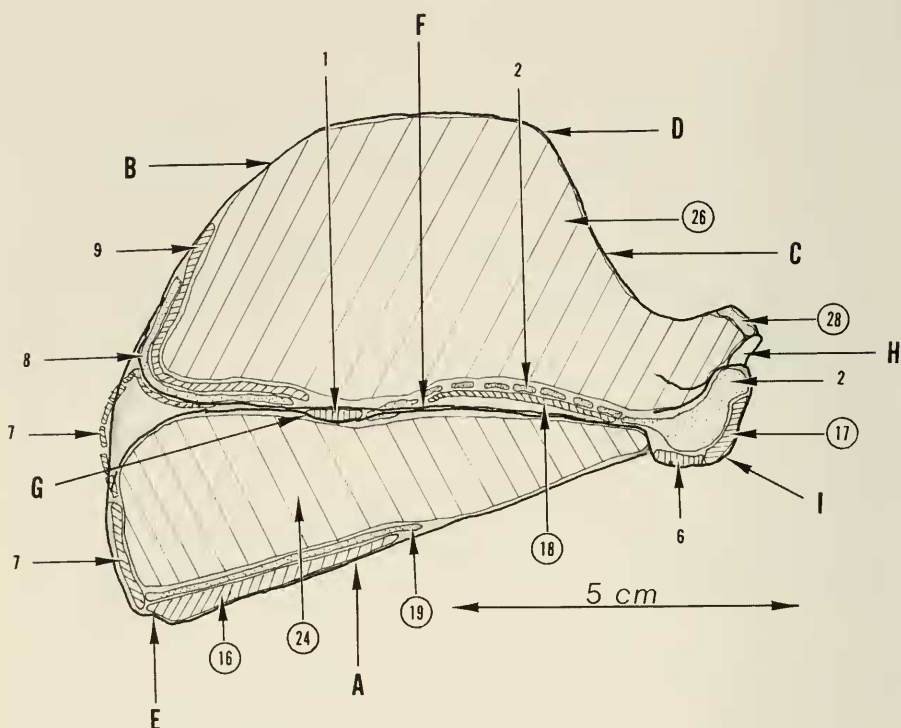


FIGURE 60. Right scapula, lateral surface. Key: 16, teres major (origin); 17, acromiodeltoideus (origin); 18, spinodeltoideus (origin); 19, dorsoepitrochlearis (origin); 24, infraspinatus (origin); 26, supraspinatus (origin); 28, biceps brachii (origin); 1, spinotrapezius (insertion); 2, acromiotrapezius (insertion); 6, omotracheon (insertion); 7, rhomboideus major (insertion); 8, rhomboideus capitis (insertion); 9, rhomboideus profundus (insertion); A, axillary border of scapula; B, vertebral border of scapula; C, superior border of scapula; D, superior angle of scapula; E, inferior angle of scapula; F, spine of scapula; G, tuberosity of scapular spine; H, glenoid surface; I, acromion process.

tendon forms which passes to the ulnar side of the radial sesamoid and dips deeply into the palm.

INSERTION. This tendon inserts on the volar surface of the base of metacarpal 2.

ACTION. Strong palmar flexion of the wrist results from a pull on this tendon.

44. **Pronator teres.**

This is a strong thick muscle passing from the medial side of the distal humerus to the radius.

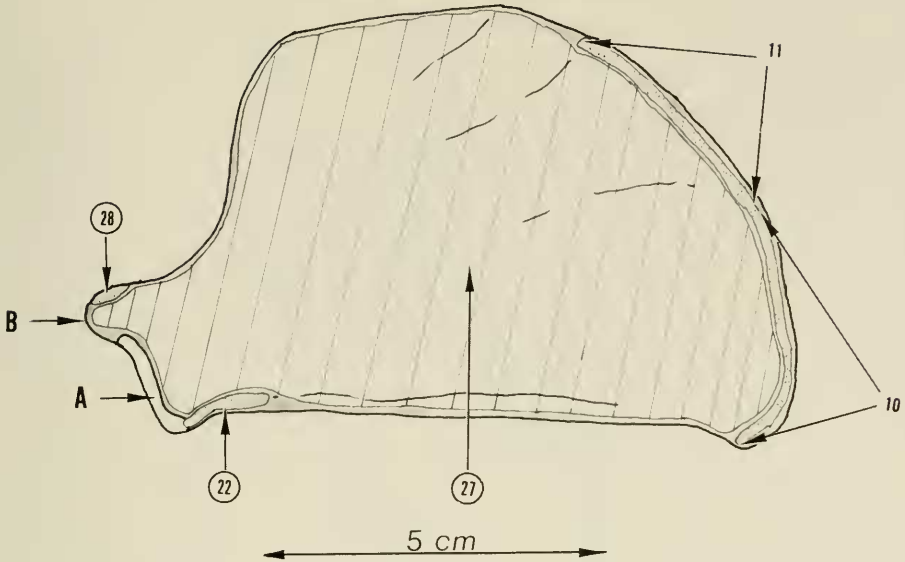


FIGURE 61. Right scapula, medial surface. Key: 22, triceps brachii caput medialis (origin); 27, subscapularis (origin); 28, biceps brachii (origin); 10, serratus magnus (insertion); 11, levator anguli scapulae (insertion); A, glenoid; B, supraglenoid tubercle.

ORIGIN. This muscle is the most proximal of those arising from the medial humeral epicondyle, but the distal one-half of the origin underlies the origin of the flexor carpi radialis. Arising mostly by tendinous fibers, this muscle diagonally crosses the upper forearm and spreads out as it approaches the radius.

INSERTION. Starting along the radial margin of the ridge of the radius, the insertion continues distally the full length of the bone. Tendinous fibers make up the insertion for the most part, with a heavy concentration of fibers at the maximum bow of the radius where the insertion comes in close relationship to the insertion of the supinator muscle. Tendinous fibers continue in lesser concentration along the distal radius to the volar aspect of the radial styloid where they lie adjacent to the insertion of the brachioradialis muscle.

ACTION. As an antagonist to supination, this muscle is a strong pronator of the forearm.

45. *Flexor digitorum profundus* (central head).

The deepest of the flexor profundus group, this muscle is roughly Y-shaped and arises in the upper forearm to join with the ulnar and humeral heads of the flexor digitorum profundus to give flexor action to the digits.

ORIGIN. There are three areas of origin of this muscle. The ulnar portion arises as fleshy fibers from the anteromedial surface of the upper two-thirds

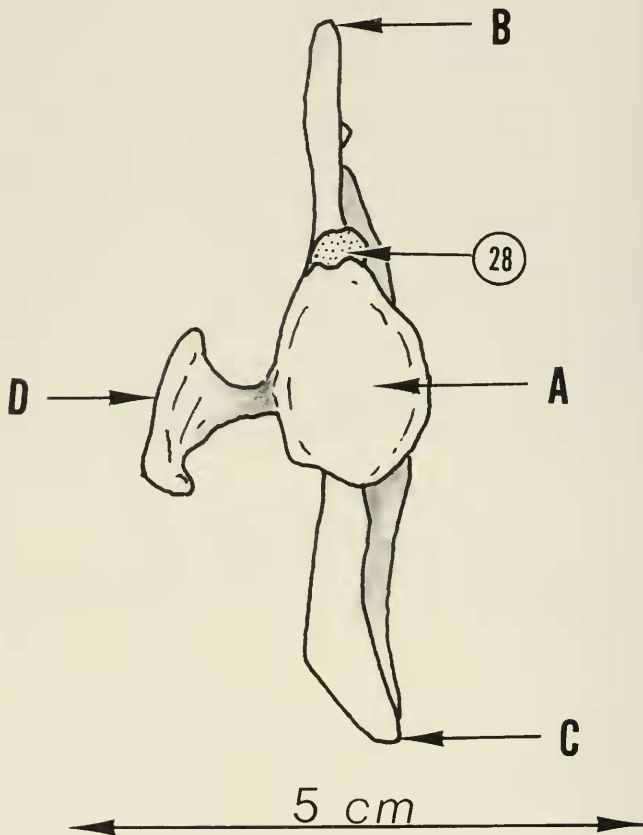


FIGURE 62. Right scapula, glenoid view. Key: 28, biceps brachii (origin); A, glenoid; B, superior angle of scapula; C, inferior angle of scapula; D, acromion process.

of the ulna. The origin starts near the articular lip of the ulna and adjacent and lateral to the tendons of insertion of the brachialis and pectoantebrachialis muscles. The radial portion arises from the anteromedial surface of the upper two-thirds of the radius, starting near the articular rim at the neck of the radius and just lateral to the bicipital tubercle. The interosseus portion arises from the volar surface of the interosseus membrane between the radius and the ulna, at the upper margin of the membrane. The muscle thus formed is flat and underlies the other profundi musculature which it joins from the underside at the level where the tendons begin to form. Distally, the flexor profundus musculature overlies the pronator quadratus muscle.

INSERTION. The muscle fibers join into the flexor digitorum profundus (central and ulnar heads) which contributes to the tendons formed and therefore has a common insertion with them.

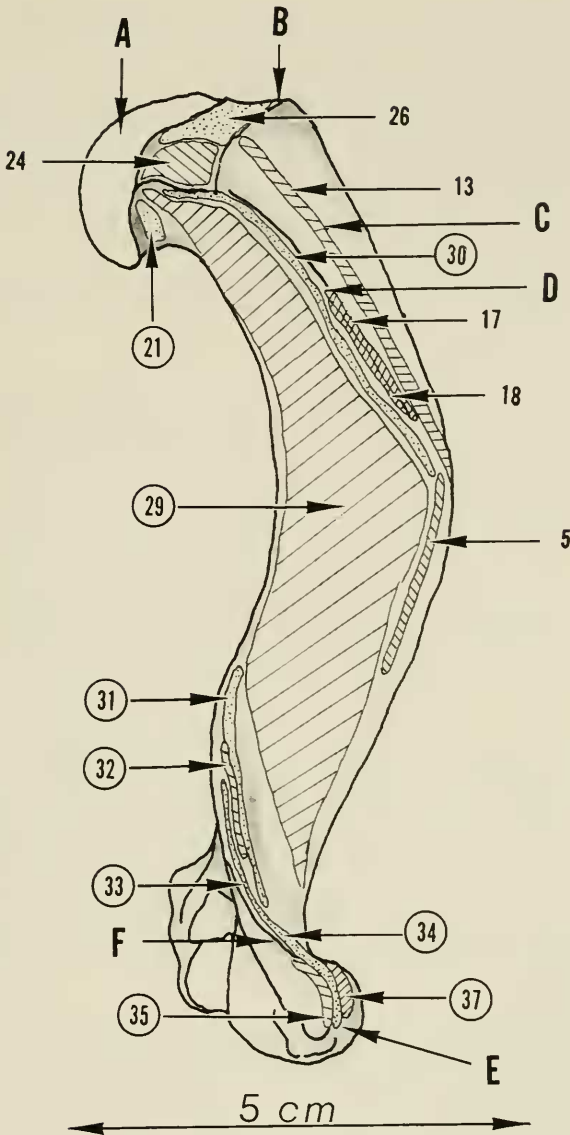


FIGURE 63. Right humerus, posterior view. Key: 21, triceps brachii caput lateralis (origin); 29, brachialis (origin); 30, brachioradialis (origin); 31, extensor carpi radialis longus (origin); 32, extensor carpi radialis brevis (origin); 33, extensor digitorum communis (origin); 34, extensor digitorum lateralis (origin); 35, extensor carpi ulnaris (origin); 37, supinator (origin); 5, clavobrachialis (insertion); 13, pectoralis major (insertion); 17, acromiodeltoideus (insertion); 18, spinodeltoideus (insertion); 24, infraspinatus (insertion); 26, supraspinatus (insertion); A, head of humerus; B, greater tuberosity; C, pectoral ridge; D, deltoid ridge; E, lateral epicondyle; F, lateral epicondylar ridge.

46. *Pronator quadratus.*

This muscle is flat and thin with fibers running transversely. It lies in the distal forearm connecting the radius and ulna.

ORIGIN. Flethy and tendinous fibers arise from the distal one-third of the medial surface of the ulna. From its origin, the muscle fibers pass directly transversely to the radius maintaining full width of the muscle.

INSERTION. Flethy and tendinous fibers insert into the distal one-fourth of the volar surface of the radius adjacent to the lower part of the insertion of the pronator teres muscle.

ACTION. Pronation of the forearm is accomplished by this muscle.

47 and 48. *Flexor digitorum sublimis.*

There are four small flexor sublimi tendons, one each for digits 2, 3, 4, and 5. Digit 1 is without a sublimis tendon. The flexor sublimis of digit 5 has been previously described under the palmaris longus muscle.

ORIGIN. The flexor sublimis tendons for digits 2, 3, and 4, arise from the volar surface of the flexor digitorum profundus complex just proximal to the wrist. The sublimis for digit 4 comes from the ulnar head, those for digits 2 and 3 from the humeral head. Because of their origin and position in the hand, they have been grouped as (47) flexor digitorum sublimis (radial) for digits 2 and 3, and (48) flexor digitorum sublimis (ulnaris) for digits 4 and 5.

INSERTION. The sublimis tendons of digits 2, 3, 4, and 5 enter the digital fibrous flexor tendon sheaths superficially to the profundus flexor tendons. At this point, each is strongly reinforced by palmar fascia fibers to form a wide flat tendon overlying and completely covering the profundus tendon. After a short distance within the sheaths, the sublimis tendons abruptly split longitudinally and curve around on either side of the profundus to rejoin into a thin but broad tendon which hugs the proximal phalanx forming the back wall of the flexor sheaths. The sublimi tendons continue distally across the proximal interphalangeal joint to a broad insertion on the volar lip of the proximal end of the middle phalanx.

ACTION. The sublimi tendons act to flex the proximal interphalangeal joints of digits 2, 3, 4, and 5. In view of their origin, those of digits 2, 3, and 4 must function in relation to the profundus flexor tendons. For digit 5, the anatomy would allow for some independent flexion of the proximal interphalangeal joint. The broad spread of the sublimis tendons at metacarpal-phalangeal joint level could also serve as a pulley mechanism for the profundus tendons.

THE INTRINSIC MUSCLES OF THE HAND

A group of small muscles within the hand proper have been termed intrinsic hand muscles. In view of their size, these muscles are not strong but they serve

a most important function in balancing the action of the long forearm flexor and extensor musculature. These muscles, also, can provide the fine skill motion of the digits. This latter function can hardly be recognized in the sea otter as the digits are in the state of syndactyly and the thumb is unopposable.

For descriptive purposes, these intrinsic muscles can be grouped as follows. Those about the first ray are called the thenar intrinsic muscles. Those about the fifth ray are called the hypothenar intrinsic muscles. The remaining small muscles consist of the interossei, one each for the second, third, and fourth digits, and two accessory intrinsic muscles for digit 2.

Also, the lumbrical muscle is generally considered an intrinsic muscle, although its origin is from the flexor digitorum profundus group of tendons.

THE HYPOTHENAR GROUP OF INTRINSIC HAND MUSCLES

49. *Abductor digiti quinti*.

This is a rather large coarse muscle forming the ulnar border of the hand.

ORIGIN. Fleishy fibers arise from a triangular area on the distal surface of the pisiform bone. The muscle becomes spindle-shaped passing distally.

INSERTION. The insertion is through a sesamoid bone into the ulnar volar aspect of the base of the proximal phalanx.

ACTION. This muscle flexes the metacarpal phalangeal joint of digit 5 and would also serve to abduct the extended digit within its anatomical limits.

50. *Opponens digiti quinti*.

This is a superficial slender fusiform muscle of the hypothenar group.

ORIGIN. Fleishy and tendinous fibers arise from the ulnar side of the deep carpal ligament to form the thin muscle which first overrides the long flexors of the fifth digit, then passes more deeply into the palm on a slightly oblique course to overlie the adductor and flexor digiti quinti. At the metacarpal phalangeal joint level a small thin tendon forms.

INSERTION. The insertion is into the volar aspect of the base of the proximal phalanx of digit 5 just to the ulnar side of the tendinous insertion of the adductor digiti quinti.

ACTION. The position of this muscle would provide slight opposition action to the fifth ray if such were possible. The muscle probably serves to assist in independent flexion of the metacarpal-phalangeal joint.

51. *Flexor digiti quinti brevis*.

This muscle is small and deep in the palm, being in the general plane of the interossei muscles of the adjacent digits.

ORIGIN. This muscle arises from the fibrous capsule of the wrist joint to the ulnar side of the flexor carpi ulnaris tendon. A fusiform muscle is formed which passes directly to the radial side of digit 5 where a small tendon forms.

INSERTION. This small tendon inserts into the base of the proximal phalanx and on the radial side dorsal to the insertion of the adductor and opponens muscles.

ACTION. Flexion of the metacarpal-phalangeal joint of the fifth digit is accomplished by this muscle and also some degree of adduction.

52. *Adductor digiti quinti.*

This flat triangular muscle is the next most superficial of the hypothenar group.

ORIGIN. Fleishy fibers arise over a broad area of the volar fibrous wrist-joint capsule adjacent to and on the ulnar side of the origin of the adductor pollicis and extend ulnaward to the margin of the flexor carpi ulnaris tendon. The muscle from its origin triangulates distally and obliquely toward the base of the proximal phalanx of the fifth digit.

INSERTION. A short tendon arises which inserts into the base of the proximal phalanx on the ulnar side just radial to the opponens digiti quinti and overlying the insertion of the flexor digiti quinti brevis.

ACTION. The action of this muscle is to adduct the fifth digit and also to assist in flexion of the metacarpal-phalangeal joint.

THE LUMBRICAL MUSCLE

53. *Lumbricali.*

This small intrinsic hand muscle differs from the other by virtue of its origin.

ORIGIN. Arising from the opposed surfaces of the profundus flexor tendons of digits 3 and 4 in the proximal palm, the fleshy fibers form a short slim muscle which traverses the palm partly by a very thin tendon which passes to the radial side of digit 4.

INSERTION. This small tendon inserts into the radial side of the proximal phalanx of digit 4 just distal to the joint surface. The tendon fibers terminate into the periosteum and bone rather than entering into the extensor aponeurosis.

ACTION. Owing to its site of insertion, the muscle gives radiolateral motion of the metacarpal-phalangeal joint and also flexion of this joint.

NOTES. The number of lumbrical muscles is variable. In another specimen three lumbrical muscles were noted.

THE THENAR INTRINSIC MUSCLES

54. *Abductor pollicis brevis.*

This is a small fusiform muscle on the radial side of digit 1.

ORIGIN. Fleishy fibers arise, half from the radial sesamoid and half from

the adjacent deep carpal ligament to form a small muscle which passes along the radial side of the metacarpal adjacent to the radial portion of the flexor pollicis brevis.

INSERTION. This small muscle terminates distally in a tendon which joins with the tendon of the radial part of the flexor pollicis brevis to insert in the radial volar side of the base of the proximal phalanx through a sesamoid bone.

ACTION. The principle action is flexion of the metacarpal-phalangeal joint of digit 1. A minor degree of abduction is probably also obtained.

55. *Flexor pollicis brevis.*

This muscle, which divides near its insertion, is the deepest of the thenar group.

ORIGIN. Fleшы fibers arise from the volar fibrous wrist joint capsule between the origin of the adductor pollicis and the abductor pollicis brevis. The muscle then passes distally overlying the proximal area of the metacarpal of digit 1. The muscle then divides into radial and ulnar halves. The terminal tendon of each half inserts into the base of the proximal phalanx, the radial half through the sesamoid with a tendon of the short abductor, the ulnar half with the tendon of the adductor pollicis.

ACTION. Both halves serve as flexors of the metacarpal-phalangeal joint of digit 1.

56. *Adductor pollicis.*

This muscle is the largest of the thenar group.

ORIGIN. Fleшы fibers arise from the volar fibrous capsule of the wrist joint between the origin of the flexor pollicis brevis on the radial side and the adductor digiti quinti on the ulnar side. The origin of this muscle overlies the origin of the deeper intrinsic muscles of the second digit. The muscle thus formed courses obliquely radiusward across the palm to the ulnar side of the proximal phalanx of digit 1.

INSERTION. The short flat tendon which forms overrides but joins with the tendon of the ulnar part of the flexor pollicis brevis to insert on the ulnar volar lateral aspect of the proximal phalanx of digit 1.

ACTION. This muscle will adduct and flex the metacarpal-phalangeal joint of digit 1.

THE ACCESSORY INTRINSIC MUSCLES OF DIGIT 2

57. *Abductor digiti secundi.*

This muscle is a short, somewhat thick, muscle which overlies the interosseal musculature.

ORIGIN. Fleшы fibers arise from the volar surface of the base of metacarpal

1. The muscle then passes slightly obliquely across the thumb web to the radial side of the base of the proximal phalanx of digit 2.

INSERTION. Tendinous fibers developing at this level have a dual insertion. The more superficial fibers form a sheetlike aponeurosis which passes dorsally into the extensor hood and dorsal extensor aponeurosis. The deeper fibers join with the tendon at the radial part of the interosseus muscle for this digit and insert through a sesamoid bone into the base of the radial side of the proximal phalanx.

ACTION. The more superficial fibers which join with the extensor aponeurosis act to extend the proximal interphalangeal joint and to flex the metacarpal-phalangeal joint. The deeper fibers serve to radially flex the metacarpal-phalangeal joint.

58. *Adductor digiti secundi.*

This slender fusiform muscle lies in the same plane with the abductor digiti secundi and also overlies the deeper interossei muscles.

ORIGIN. Fleishy fibers arise from a small area of fibrous capsule at the base of metacarpal 3 slightly proximal and to the ulnar side of the origin of the interosseus of digit 2. The muscle then passes slightly obliquely and distally to the ulnar side of digit 2 where a short tendon develops.

INSERTION. At the metacarpal-phalangeal joint level the tendon passes close to the volar plate and sesamoid bone and volar to the tendon of the ulnar half of the interosseus muscle of this digit. The insertion is into the base of the proximal phalanx on the ulnar side.

ACTION. This muscle would adduct digit 2 at the metacarpal-phalangeal joint level and also assist in flexion of this joint.

THE INTEROSSEI MUSCLES

59. *Interossei.*

These muscles, three in number, are the deepest intrinsic muscles of the hand. They are short and thick and somewhat fusiform in shape. Each muscle divides about halfway from its origin into radial and ulnar halves which then pass to the respective sides of each digit at metacarpal-phalangeal joint level.

ORIGIN. All interossei muscles arise as fleshy fibers from the volar aspect of the fibrous capsule at the base of the metacarpals. Interosseus 2 between metacarpals 2 and 3, interosseus 3 at the base of metacarpal 3, and interosseus 4 at the base of metacarpal 4. The ulnar half of interosseus 4 is the largest of the interossei divisions and shows a slight tendency toward further division in its distal one-third.

INSERTION. With the exception of the radial half of interosseus 2, all interossei form flattened tendons passing close to the volar plate at metacarpal-

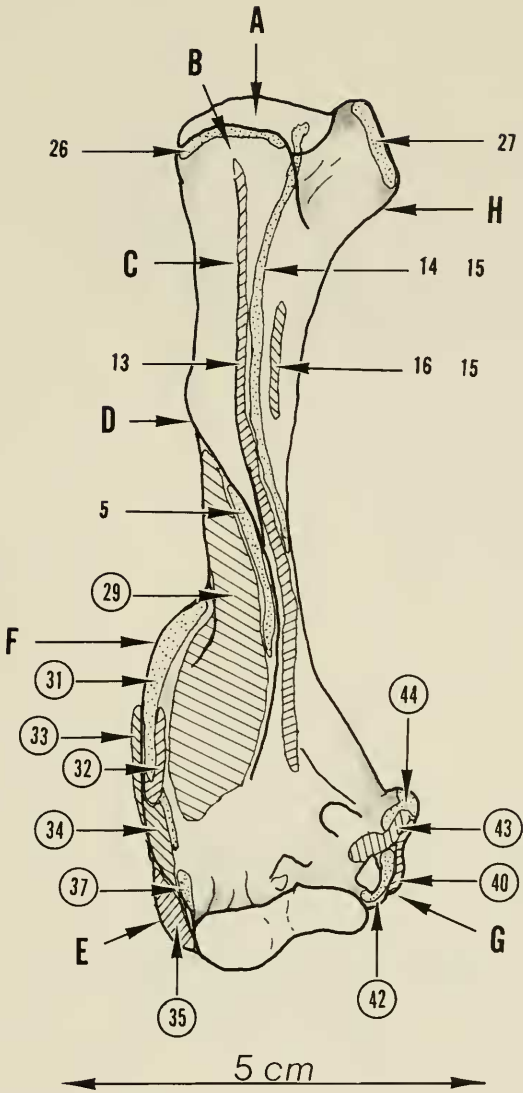


FIGURE 64. Right humerus, lateral view. Key: 29, brachialis (origin); 31, extensor carpi radialis longus (origin); 32, extensor carpi radialis brevis (origin); 33, extensor digitorum communis (origin); 34, extensor digitorum lateralis (origin); 35, extensor carpi ulnaris (origin); 37, supinator (origin); 40, palmaris longus (origin); 42, flexor digitorum profundus (humeral head—origin); 43, flexor carpi radialis (origin); 44, pronator teres (origin); 5, clavobrachialis (insertion); 13, pectoralis major (insertion); 14, pectoralis minor (insertion); 15, latissimus dorsi (insertion); 16, teres major (insertion); 26, supraspinatus (insertion); 27, subscapularis (insertion); A, head of humerus; B, greater tuberosity; C, pectoral ridge; D, deltoid ridge; E, lateral epicondyle; F, lateral epicondylar ridge; G, medial epicondyle; H, lesser tuberosity.

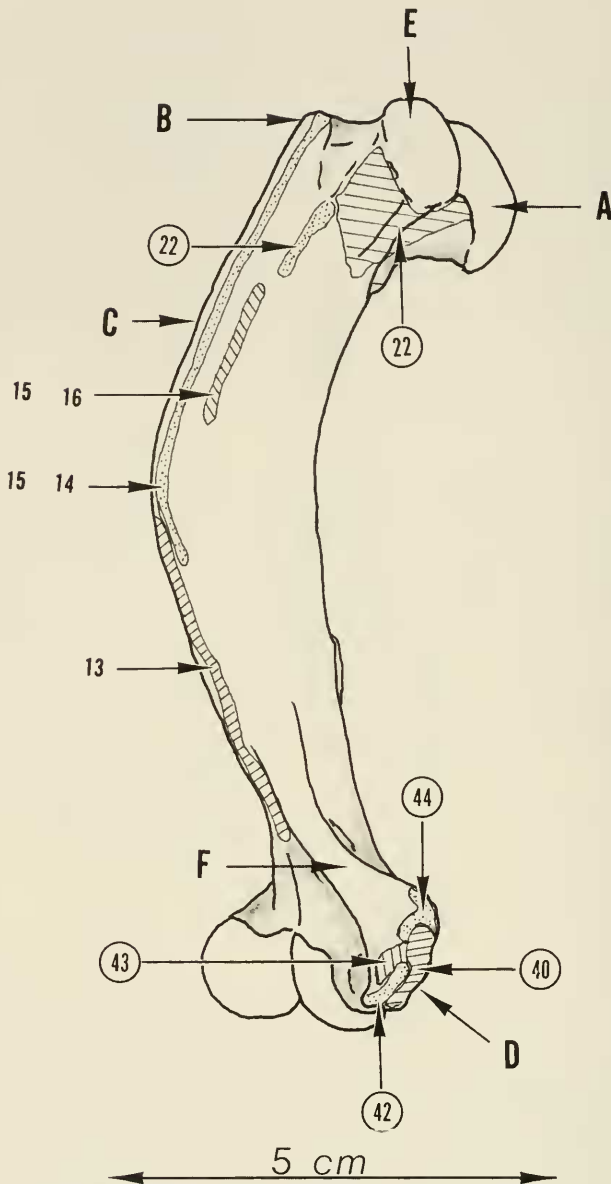


FIGURE 65. Right humerus, anterior view. Key: 22, triceps brachii caput medialis (two of three sites of origin); 40, palmaris longus (origin); 42, flexor digitorum profundus (humeral head—origin); 43, flexor carpi radialis (origin); 44, pronator teres (origin); 13, pectoralis major (insertion); 14, pectoralis minor (insertion); 15, latissimus dorsi (insertion); 16, teres major (insertion); A, head of humerus; B, greater tuberosity; C, pectoral ridge; D, medial epicondyle; E, lesser tuberosity; F, medial epicondylar ridge.

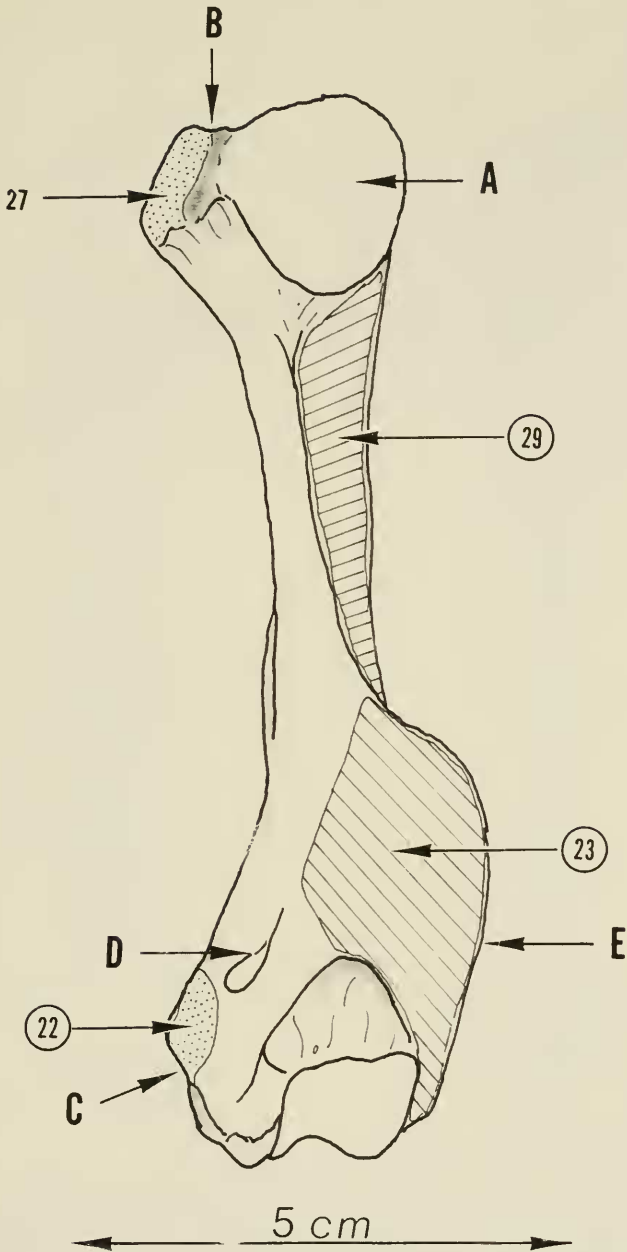


FIGURE 66. Right humerus, medial view. Key: 22, triceps brachii caput medialis (origin); 23, anconeus externus (origin); 29, brachialis (origin); 27, subscapularis (insertion); A, head of humerus; B, lesser tuberosity; C, medial epicondyle; D, medial epicondylar foramen; E, lateral epicondylar ridge.

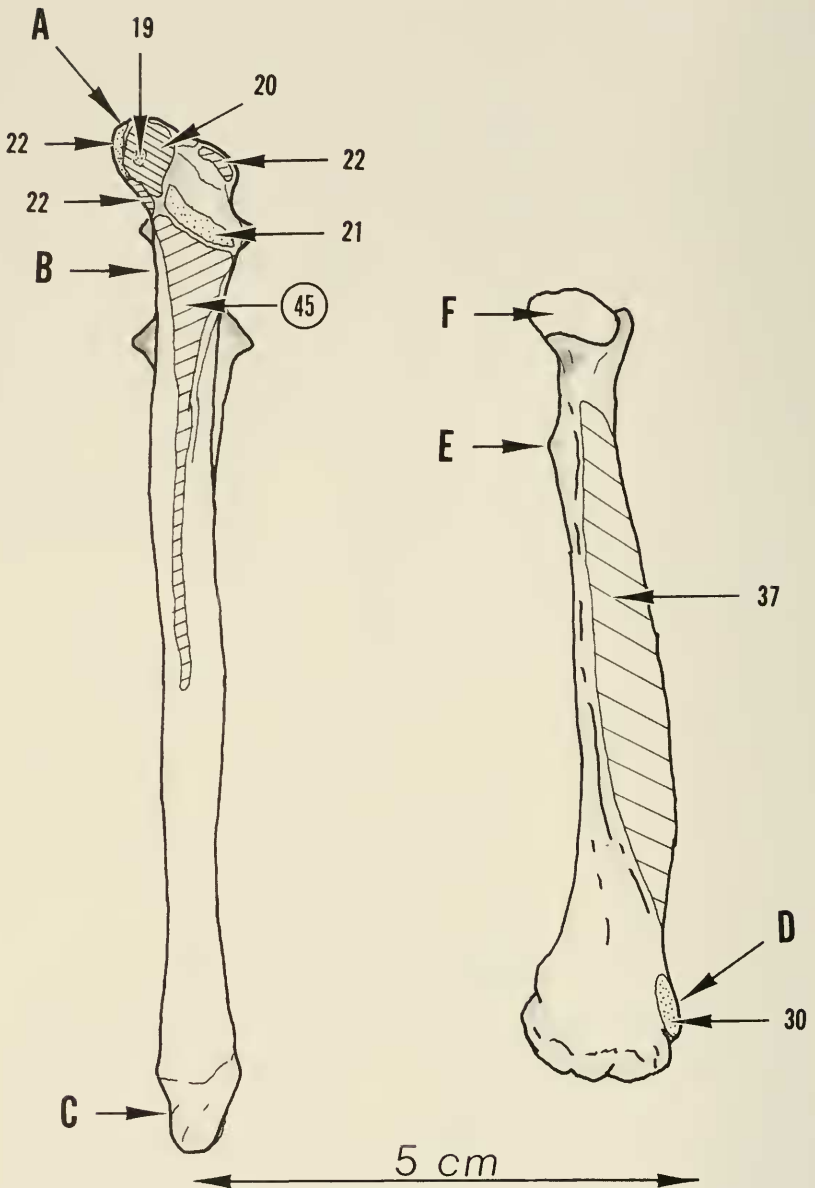


FIGURE 67. Right ulna and radius, posterior view. Key: 45, flexor digitorum profundus (humeral head—origin); 19, dorsoepitrochlearis (insertion); 20, triceps brachii caput longus (insertion); 21, triceps brachii caput lateralis (insertion); 22, triceps brachii caput medialis (insertion); 30, brachioradialis (insertion); 37, supinator (insertion); A, olecranon process of ulna; B, semilunar notch; C, styloid process; D, radial styloid; E, biceps tubercle of radius; F, head of radius.

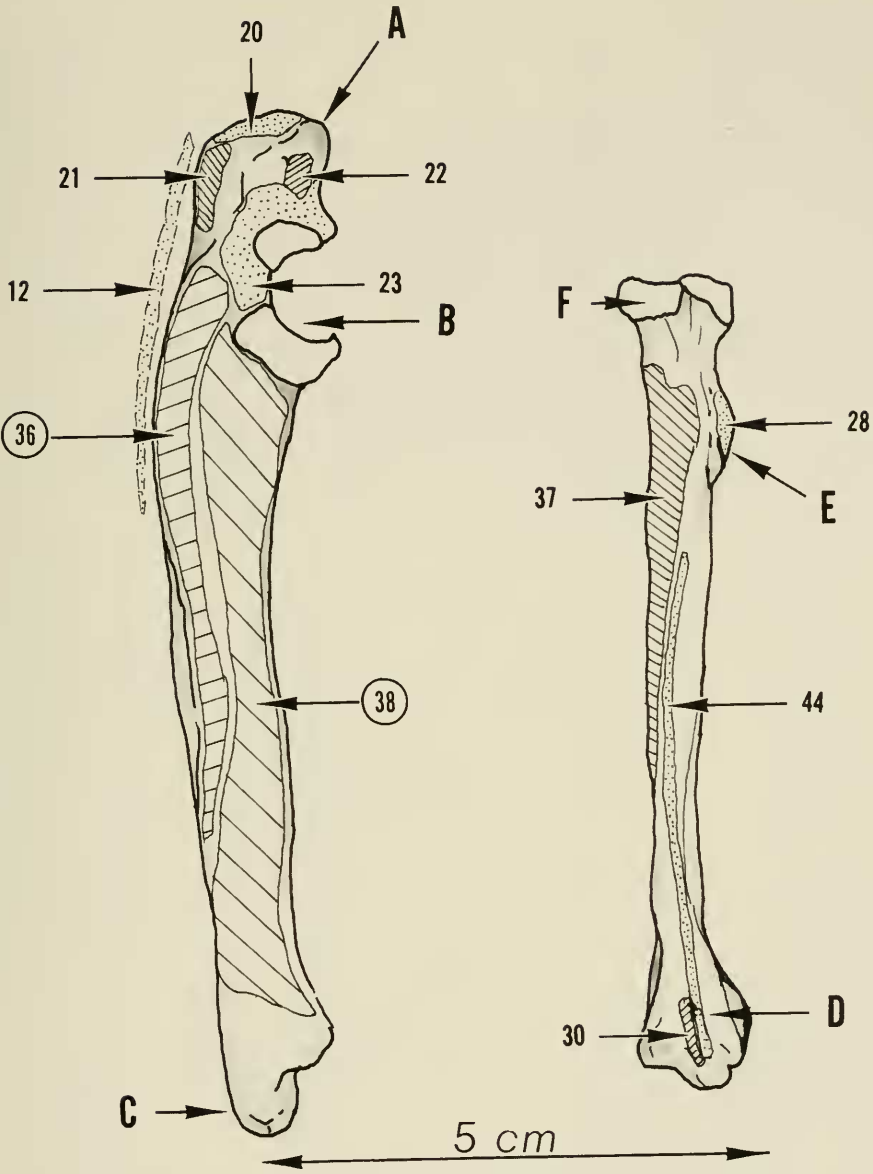


FIGURE 68. Right ulna and radius, lateral view. Key: 36, extensor pollicis et indicis longus (origin); 38, abductor pollicis longus (origin); 12, pectoantebrachialis (into fascia—insertion); 20, triceps brachii caput longus (insertion); 21, triceps brachii caput lateralis (insertion); 22, triceps brachii caput medialis (insertion); 23, anconeus externus (insertion); 28, biceps brachii (insertion); 30, brachioradialis (insertion); 37, supinator (insertion); 44, pronator teres (insertion); A, olecranon process, ulna; B, semilunar notch; C, styloid process, ulna; D, styloid process, radius; E, bicipital tuberosity; F, head of radius.

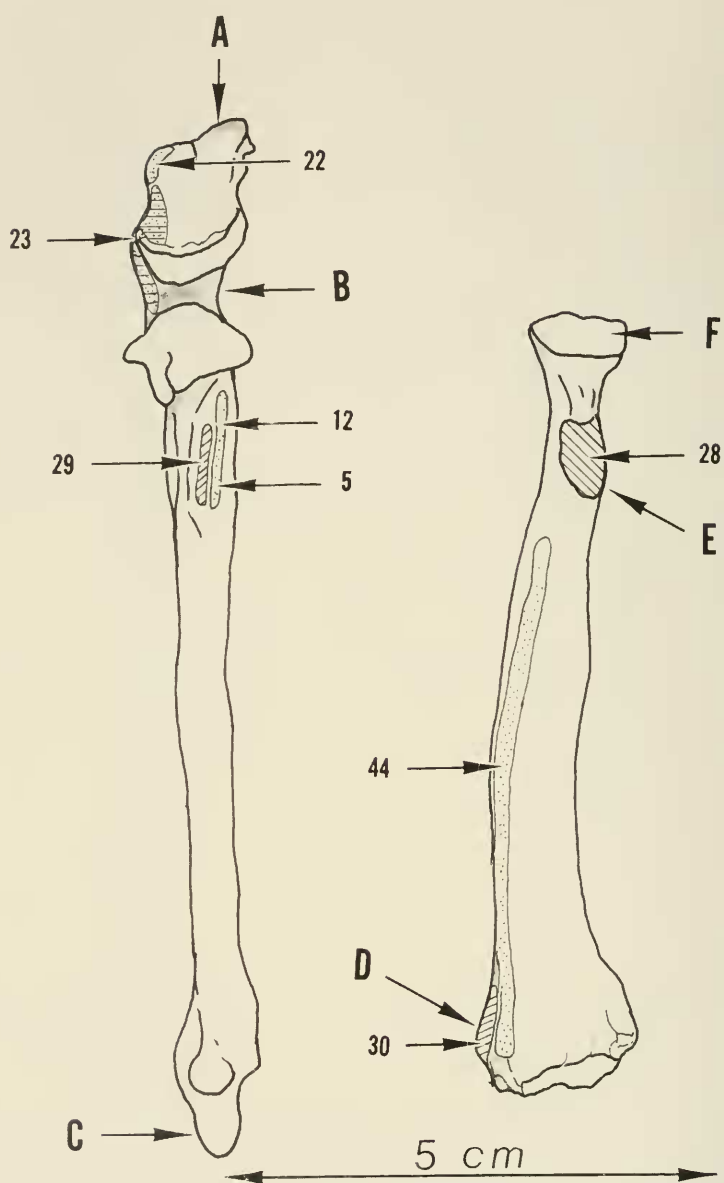


FIGURE 69. Right ulna and radius, anterior view. Key: 5, clavobrachialis (insertion); 12, pectoantibrachialis (insertion); 22, triceps brachii caput medialis (insertion); 23, anconeus externus (insertion); 28, biceps brachii (insertion); 29, brachialis (insertion); 30, brachioradialis (insertion); 44, pronator teres (insertion); A, olecranon process, ulna; B, semilunar notch; C, styloid process, ulna; D, styloid process, radius; E, bicipital tuberosity; F, head of radius.

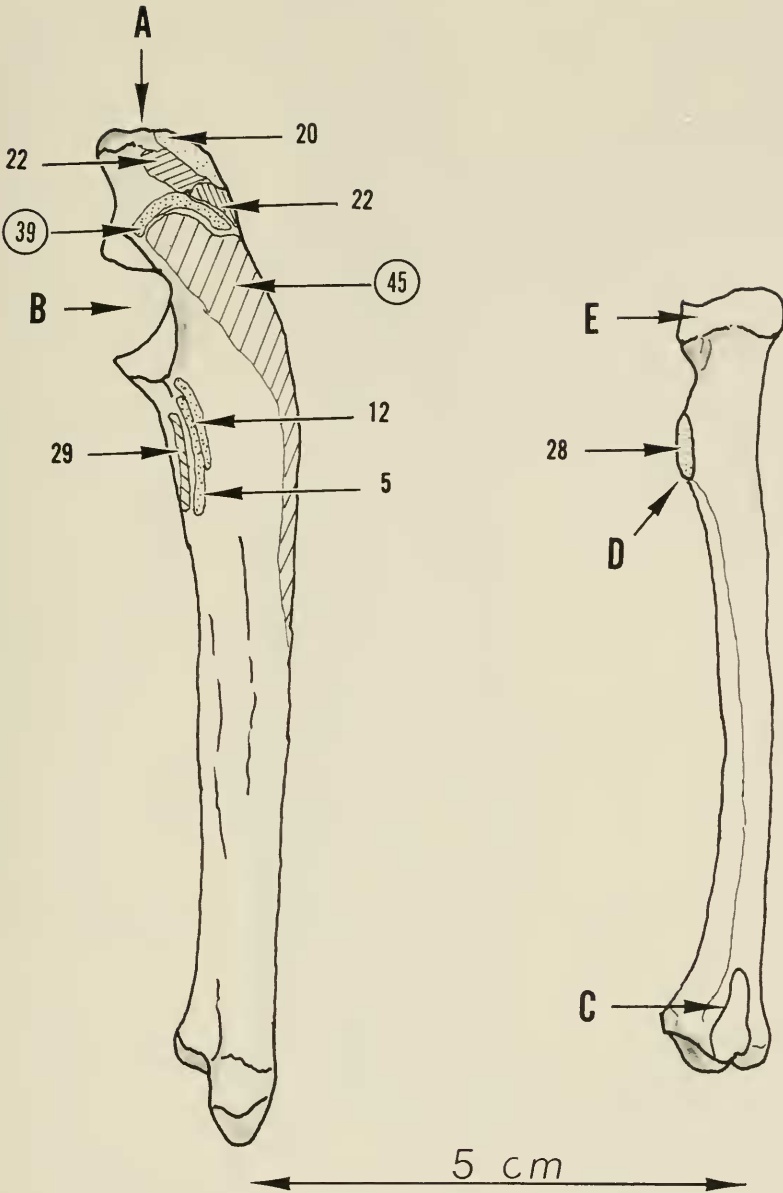


FIGURE 70. Right ulna and radius, medial view. Key: 39, flexor carpi ulnaris (origin); 45, flexor digitorum profundus (central head—origin); 5, clavobrachialis (insertion); 12, pectoantebrachialis (insertion); 20, triceps brachii caput longus (insertion); 22, triceps brachii caput medialis (insertion); 28, biceps brachii (insertion); 29, brachialis (insertion); A, olecranon process, ulna; B, semilunar notch, ulna; C, articular surface for ulna; D, bicipital tubercle, radius; E, radial head.

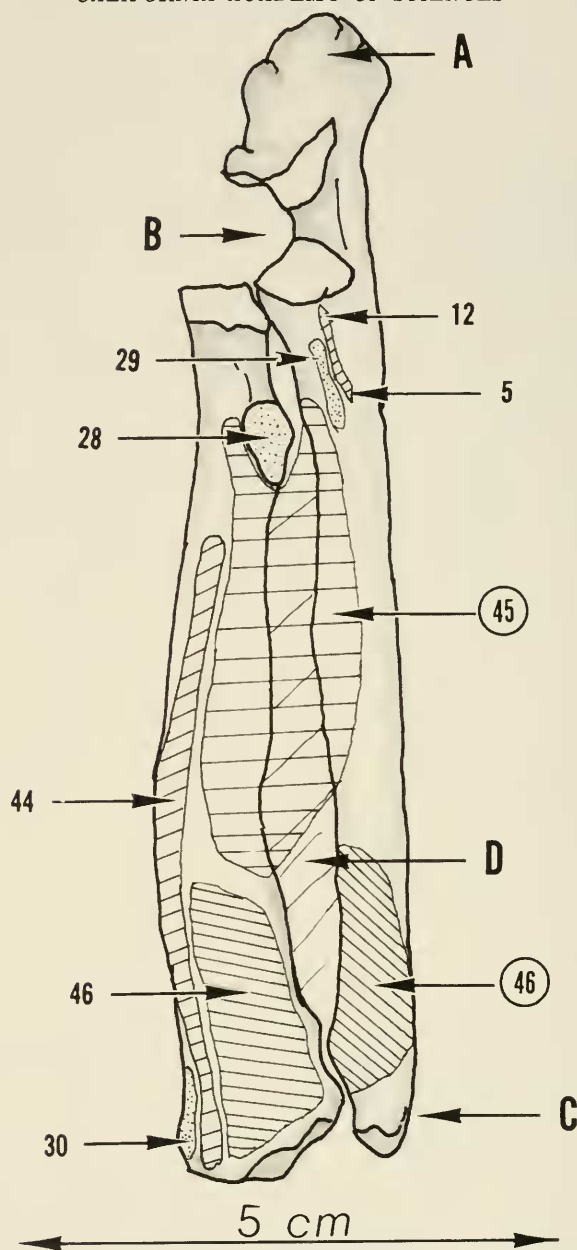


FIGURE 71. Right ulna and radius, articulated, anterior view. Key: 45, flexor digitorum profundus (central head—origin); 46, pronator quadratus (origin); 5, clavobrachialis (insertion); 12, pectoantebrachialis (insertion); 28, biceps brachii (insertion); 29, brachialis (insertion); 30, brachioradialis (insertion); 44, pronator teres (insertion); 46, pronator quadratus (insertion); A, olecranon process, ulna; B, semilunar notch, ulna; C, styloid process, ulna; D, interosseus membrane.

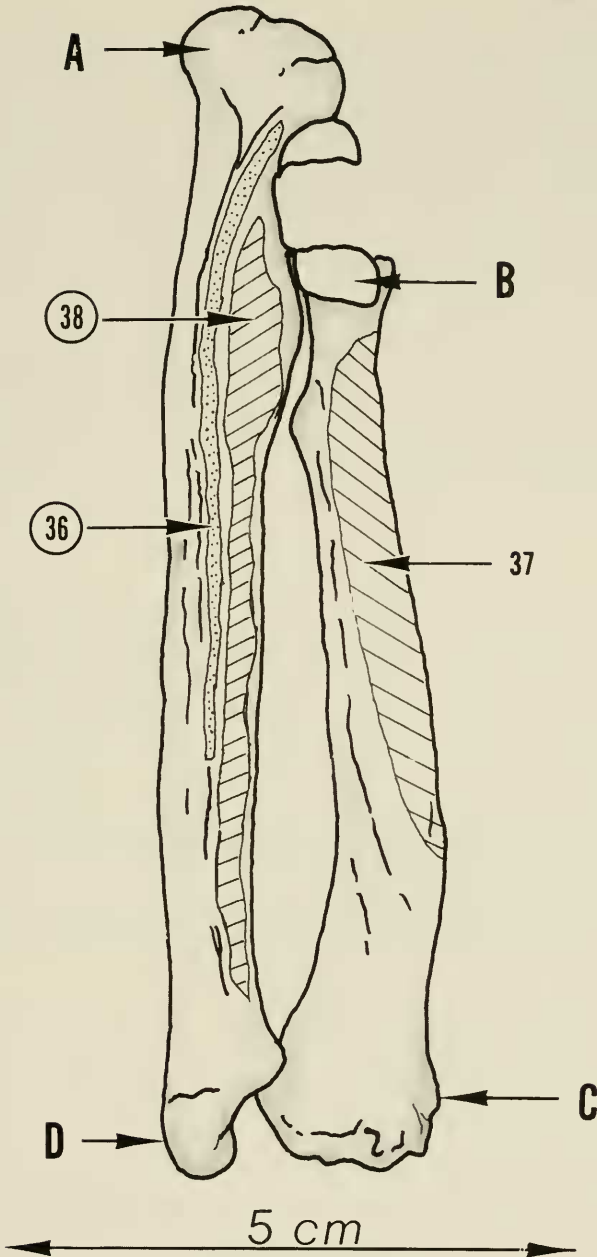


FIGURE 72. Right ulna and radius, articulated, posterior view. Key: 36, extensor pollicis et indicis longus (origin); 38, abductor pollicis longus (origin); 37, supinator (insertion); A, olecranon process, ulna; B, head of radius; C, styloid process, radius; D, styloid process, ulna.

phalangeal joint level and then, as aponeurotic sheets, join into the extensor hood and extensor aponeurosis of each digit forming the lateral band of the extensor aponeurosis. At the proximal interphalangeal joint level, these lateral bands and extensor aponeuroses terminate into the central extensor tendon to insert into the dorsum at the base of the middle phalanx. The extensor tendon structures do not continue to the terminal phalanx as might be expected. The tendon of the radial half of the interosseus 2 joins with the tendon of the abductor digiti secundi to insert through a sesamoid into the base of the proximal phalanx as previously described.

ACTION. The interossei tendons joining into the extensor aponeurosis serve to balance the action between the long extensor and flexors of these digits. Acting alone, they would impart lateral motion to the extended digits or serve to flex independently the metacarpal-phalangeal joints. With the metacarpal-phalangeal joints in hyperextension, they would also act to extend the proximal interphalangeal joints. In this way, the balancing effect prevents deformity from action of the long extensors and flexor tendons alone.

MUSCLE ORIGINS AND INSERTIONS

In viewing the origin and insertion of the muscles as shown in the skeletal figures, some confusion may arise owing to the bowing and torsion of the long bones, particularly the humerus. The views as described of each plate are based on the proximal ends of the bones. For example, a posterior view of the proximal end of the humerus gives, as a result of torsion of this bone, a lateral view of the distal end.

Each muscle retains its individual number and, therefore, to distinguish between origin and insertion a circled number means the area of origin and an uncircled number means the area of insertion.

The bones of the forefoot are not shown, as tendon insertions only are present and these areas of insertion are shown quite adequately on the muscle plates.

SUMMARY

The gross muscular anatomy of the forelimb of the sea otter has been presented. For the hand the intrinsic and extrinsic musculature is sufficient to provide for dexterity, but such is extremely limited by reason of the anatomical restrictions imposed by the integument and soft parts.

The forefoot, obviously designed for terrestrial use, has become, by virtue of bimanual use, a highly skilled appendage for other purposes.

ACKNOWLEDGMENTS

The State of California Department of Fish and Game was most cooperative in providing the specimen for anatomical study. The California Academy of Sciences provided the invaluable aid of a disarticulated sea otter skeleton.

The Anatomical Studies of the California River Otter, by Edna M. Fisher, proved to be an excellent guide during the dissection, and her unpublished notes on the sea otter anatomy, which were made available through the courtesy of Mr. Fred Tarasoff, were also of value. Unpublished notes and sketches by Fred Tarasoff were also available and of some assistance.

The dissection and storage of materials took place at the Hopkins Marine Station of Stanford University in Pacific Grove, California, and the personnel of this institution, particularly Dr. I. Abbott, gave encouragement and assistance in every way possible for which I am deeply indebted.

BIBLIOGRAPHY

BARABASH-NIKIFOROV, I. I.

1962. The sea otter (*Enhydra lutris* L.). Biology and economic problems of breeding. Translated from the Russian by the Israeli Program for Scientific Translations. National Science Foundation and U.S. Department of the Interior, Washington, D. C., 227 pages.

FISHER, EDNA M.

1939. Habits of the southern sea otter. *Journal of Mammalogy*, vol. 20, no. 1, pp. 21-36.
1942. Osteology and myology of the California river otter. Stanford University Press, Stanford, California, vi + 66 pages.
- . Notes and sketches on the myology of the southern sea otter. (Unpublished). Courtesy of Fred Tarasoff.

GOLDER, F. A.

1925. Bering's voyages. American Geographical Society, Research Series, no. 2, 290 pages.

GRINNELL, J., JOSEPH S. DIXON, and JEAN M. LINSDALE

1937. Fur bearing mammals of California. University of California Press, Berkeley, California, 777 pages.

HALL, E. R.

1926. Muscular anatomy of three mustelid mammals, *Mephitis*, *Spilogale*, and *Martes*. University of California Publications in Zoology, vol. 30, no. 2, pp. 7-38.

HALL, K. R. L.

1963. Tool-using performances as indicators of behavioral adaptability. *Current Anthropology*, vol. 4, December, pp. 479-494.

HARRIS, C. J.

1968. Otters: a study of the recent Lutrinae. Weidenfeld and Nicolson, London, 397 pages.

HOWELL, A. B.

1930. Aquatic mammals. Charles C. Thomas, Springfield, Illinois, and Baltimore, Maryland, xii + 338 pages.

JOLLIE, M.

1962. Chordate morphology. Reinhold, New York, 478 pages.

JACOBI, A.

1938. Der Seeotter. Monographien der Wildsaugetiere, Band VI, 93 pages. (Translation: Fisheries Research Board of Canada, no. 521.)

KENYON, K. W.

1969. The sea otter in the eastern Pacific Ocean. North American Fauna, no. 68, U.S. Department of the Interior, Bureau of Sport Fisheries and Wildlife, Washington, 352 pp.

MURIE, O. J.

1940. Notes on the sea otter. *Journal of Mammalogy*, vol. 21, no. 2, pp. 119-131.

ORR, R. T.

1966. *Vertebrate biology* (second edition). W. B. Saunders Co., Philadelphia, xii + 483 pages.

ROMER, A. S.

1964. *The vertebrate body*. W. B. Saunders Co., Philadelphia and London, viii + 643 pages.

SOKOLOV, A. S., and I. I. SOKOLOV

1970. Some specific features of the locomotor organs of the river otter and sea otter associated with their mode of life. *Moscovskoe Obschestvo Ispytatelei Prirody, Otdel Biologicheskii*, vol. 75, no. 5, pp. 5-17. (Translated from the Russian, Hopkins Marine Station, Pacific Grove, California, 1972.)

TAYLOR, W. P.

1914. The problem of aquatic adaptation in the Carnivora, as illustrated in the osteology and evolution of the sea otter. *University of California Publications, Bulletin of the Department of Geology*, vol. 7, no. 25, pp. 465-495.

TARASOFF, F. J.

- . Notes and sketches on the myology of the sea otter. (Unpublished.)

TARASOFF, F. J., A. BISAILLON, J. PIERARD, and A. P. WHIPT

1972. Locomotory patterns and external morphology of the river otter, sea otter, and harp seal (Mammalia). *Canadian Journal of Zoology*, vol. 50, no. 7, pp. 915-929.

VANDEVERE, J. E.

1969. Feeding behavior of the southern sea otter. *Proceedings of the Sixth Annual Conference on Biological Sonar and Diving Mammals*, Stanford Research Institute, pp. 87-94.